

FOLIA

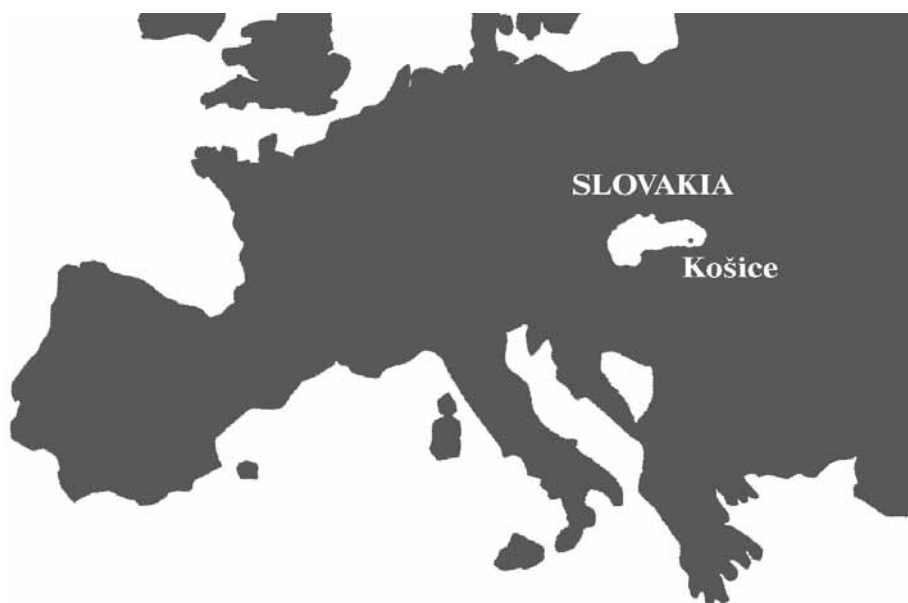VETERINARIA

The scientific journal of the
UNIVERSITY OF VETERINARY MEDICINE AND
PHARMACY IN KOŠICE — The Slovak Republic

ISSN 0015-5748



3
LV • 2011



EDITORIAL BOARD

- Editor in Chief** : Emil Pilipčinec
Executive Editor : Jaroslav Legáth
Members : Baumgartner, W. (Vienna), Bireš, J. (Košice), Buczek, J. (Lublin), Campo, M. S. (Glasgow), Cigánková, V. (Košice), Cudlín, J. (Prague), Dianovský, J. (Košice), Huszenicza, Gy. (Budapest), Korim, P. (Košice), Kottferová, J. (Košice), Kováč, G. (Košice), Levkut, M. (Košice), Máté, D. (Košice), Mojžišová, J. (Košice), Pistl, J. (Košice), Pliešovský J. (Bratislava), Pogačnik, M. (Ljubljana), Šucman, E. (Brno), Totolian, A.A. (Saint Petersburg), Vajda, V. (Košice), Valocký, I. (Košice), Vargová, M. (Košice), Večerek, V. (Brno), Vilček, Š. (Košice)

FOLIA VETERINARIA is issued by the *University of Veterinary Medicine and Pharmacy in Košice (UVMF)*; address: Komenského 73, 041 81 Košice, The Slovak Republic (tel.: +421 55 632 52 93, fax: +421 55 632 52 93, E-mail: vargova@uvm.sk).

The journal is published quarterly in English (numbers 1–4) and distributed worldwide.

Subscription rate for 1 year is 120 €. Orders are accepted by *The Department of The Scientific Information – The Library of The University of Veterinary Medicine and Pharmacy in Košice (UVIK)*, E-mail: palencarova@uvm.sk; the subscription is accepted by the State treasure.

Bank contact: State treasure, Radlinského 32, Bratislava 15, The Slovak Republic; **account number:** 7000072225/8180.

FOLIA VETERINARIA, vydáva *Univerzita veterinárskeho lekárstva a farmácie v Košiciach (UVLF)*, Komenského 73, 041 81 Košice, Slovenská republika (tel.: 055/632 52 93, fax: 055/632 52 93, E-mail: vargova@uvm.sk).

Časopis vychádza kvartálne (č. 1–4) a je distribuovaný celosvetovo.

Ročné predplatné 120 €. Objednávky prijíma *Ústav vedeckých informácií a knižnice Univerzity veterinárskeho lekárstva a farmácie v Košiciach (UVIK)*, E-mail: palencarova@uvm.sk; predplatné štátna pokladnica (na nižšie uvedené číslo účtu).

Bankové spojenie: Štátna pokladnica, Radlinského 32, Bratislava 15; **číslo účtu:** 7000072225/8180.

Tlač: **Univerzita veterinárskeho lekárstva a farmácie**
Komenského 73, 041 81 Košice

Sadzba: **Sapfo publishers**, Szakkayho 1, 040 01 Košice

EV 3485/09

For basic information about the journal see
Internet home pages: www.uvm.sk; www.uvlf.sk

Indexed and abstracted
in AGRIS, CAB, EBSCO

CONTENTS

EYAREFE, O. D., ABIOLA, J. O., OGUNTOYE, C. O., AYOADE, G. O.: ANO-RECTAL MALFORMATIONS IN PIGS: A REPORT OF A STRIKING CASE IN AN EIGHT-WEEK-OLD PIGLET (A CASE REPORT)	61
AJADI, R. A., ADENUBI, O. T., SOGEBI, E. A. O.: INFLUENCE OF MIDAZOLAM ON SOME ANAESTHETIC INDICES AND SAFETY OF KETAMINE – XYLAZINE COMBINATION IN SWINE	64
HOLOVSKÁ, K. JR., ALMÁŠIOVÁ, V., TARABOVÁ, L., CIGÁNKOVÁ, V.: EFFECT OF XENOBIOTICS ON THE STRUCTURE OF THE RABBIT'S LIVER	69
AKINLOYE, O. A., ADENIYI, T. T., ADAMSON, I.: BENEFICIAL EFFECTS OF THIAMINE, ASCORBIC ACID, AND ITS COMBINATION ON PARAQUAT TOXICITY IN RATS	73
ŠEVČÍK, A., GRUNERMELOVÁ, E., LEDECKÝ, V., ČAPÍK, I., HLUCHÝ, M., KARASOVÁ, M.: STATISTICAL EVALUATION OF IMAGES PRODUCED BY X-RAY EXAMINATION OF DOGS FROM EASTERN SLOVAKIA BETWEEN 1999 AND 2008.....	77
ŠŤAVOVÁ, E., KREŠÁKOVÁ, L.: ACETYLCHOLINE AND CHOLINESTERASE IN RELATION TO PESTICIDES AND THEIR MORPHOGENETIC ROLES (A REVIEW).....	86
LUPTÁKOVÁ, L., PETROVOVÁ, E., ŠŤAVOVÁ, E., MAŽENSKÝ, D.: COMPARISON OF COMPLEMENT FIXATION TEST AND ELISA IN THE LABORATORY DIAGNOSIS OF TOXOPLASMOSIS.....	91
RAVASZOVÁ, P., VALENČÁKOVÁ, A., LUPTÁKOVÁ, L., MALČEKOVÁ, B., GOLDOVÁ, M.: CHARACTERIZATION OF DIFFERENT PCR METHODS FOR THE IDENTIFICATION OF <i>CRYPTOSPORIDIUM</i> SPP.	95
HOLOVSKÁ, K. JR., ALMÁŠIOVÁ, V., TARABOVÁ, L., CIGÁNKOVÁ, V.: ULTRASTRUCTURAL CHANGES IN THE <i>M. GASTROCNEMIUS</i> OF JAPANESE QUAILS DURING LONG-LASTING HYPODYNAMY.....	99
AJADI, R. A., OMOBOWALE, T. O., IGADO, O. O., ADEJINMI, J. O., ADEDOKUN, O. A., NOTTIDGE, H. O.: <i>DIROFILARIA IMMITIS</i> INFECTION IN A THREE YEAR OLD DOBERMAN: A CASE REPORT	103
KORÉNEK, M., KORÉNEKOVÁ, B., SKALICKÁ, M., NAĐ, P., SOKOL, J., JALČ, P., HÚSKA, M.: INFLUENCE OF CADMIUM AND SELENIUM ON THE ACTIVITY OF TRYPSIN AND CHYMOTRYPSIN IN THE DROPPINGS OF JAPANESE QUAILS	107



ANO-RECTAL MALFORMATIONS IN PIGS: A REPORT OF A STRIKING CASE IN AN EIGHT-WEEK-OLD PIGLET (A CASE REPORT)

Eyarefe, O. D.¹, Abiola, J. O.², Oguntoye, C. O.¹, Ayoade, G. O.²

¹Department of Veterinary Surgery and Reproduction, University of Ibadan

²Department of Veterinary Medicine, University of Ibadan
Nigeria

tolamega@yahoo.com

eyarefe@mail.ui.edu.ng

ABSTRACT

Anorectal malformations are rare congenital disorders in animals. In swine, *atresia ani* occurs with an incidence of 0.1–1.0% and it is the most important cause of intestinal obstruction in that species. This paper reports a striking case of *atresia ani et recti* in an eight-week-old piglet. The surgical management and preventive measures are discussed.

Key words: anus; *atresia*; piglet; rectum

INTRODUCTION

Anorectal malformations are rare as are the severe congenital spectra of disorders that affect the terminal intestine of human beings and other animals (10). The term “imperforate anus” is presently known as a mere reflection of the most superficial appearance of the condition. The incidence of anorectal malformations is approximately 1:5000 live births in human beings (2, 11), while in swine, *atresia ani* occurs with an incidence of 0.1–1.0% (9, 15) and it is the most important cause of intestinal obstruction in this species (5).

The etiology and causal genetic factors of anorectal malformations remain poorly understood and controversial (2, 15). Some researchers have, however, suggested a possible cloacal plate devel-

opmental defect during embryogenesis resulting in none migration of the dorsal cloacal plate and the neighbouring structures to the body surface of the tail groove (2, 6, 8, 15).

The types of anorectal malformations reported so far depend on the extent of the cloacal plate defects. The types vary from minor anal stenosis such as imperforate ani (*atresia ani*) (11) to more serious defects such as *atresia recti* (15). The mode of inheritance of *atresia ani* is still relatively unclear. More so are the genetic models to explain the mode of inheritance of the disorder. A monogenic recessive model with incomplete penetration was postulated (7, 14). In contrast, a two-locus recessive model was hypothesized assuming either complete (3) or incomplete penetration (4). However, a recent comprehensive comparison of various genetic models by means of segregation analysis, favoured a mixed genetic model, where a single locus and polygenic effects are involved in the development of the congenital defects (13, 15). *Atresia ani* and *atresia recti*, may occur independently or simultaneously in the same animal. However, it is not known whether *atresia recti* and *atresia ani* have the same genetic foundation or differ only in the degree of anal malformation (15). There are also suggestions that the disease may be more pronounced in male than in female piglets (10, 14), although, some investigators have not found any difference in the occurrence between sexes (2, 11, 14). The major bias in the sex ratio of the affected piglets was associated with observations that females with *atresia ani* do survive for a longer time than males, due to the development of recto-vagina fistulae which enable them to defecate

through the vagina (9, 13). Farmers sell such females as sucking pigs rather than sending them for surgical management (13). In this paper, a case of *atresia ani et recti* in an 8-week-old male piglet is reported which to the best of our knowledge has not been reported before in Nigeria.

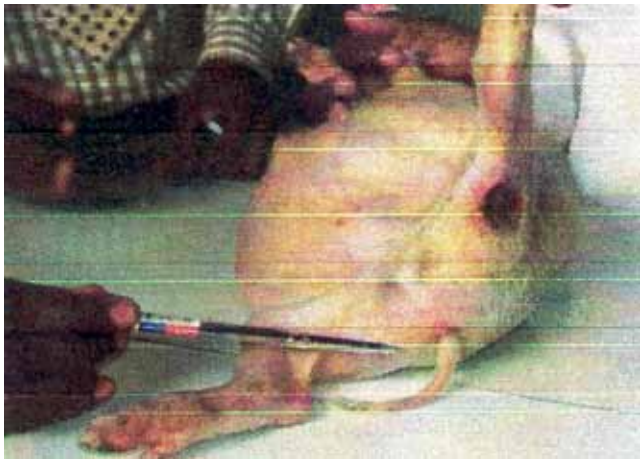

Fig. 1. Imperforate anus

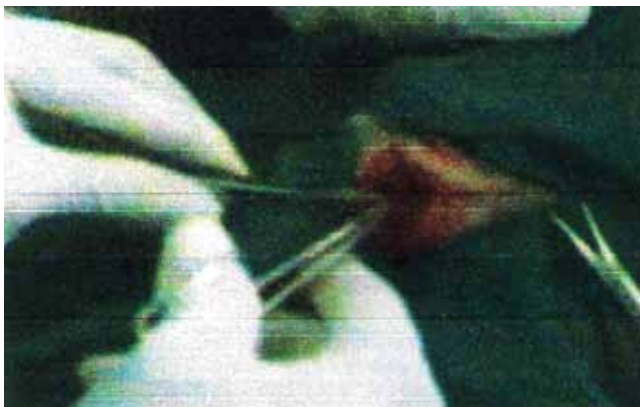

Fig. 3. Attempt to link anus through dissection

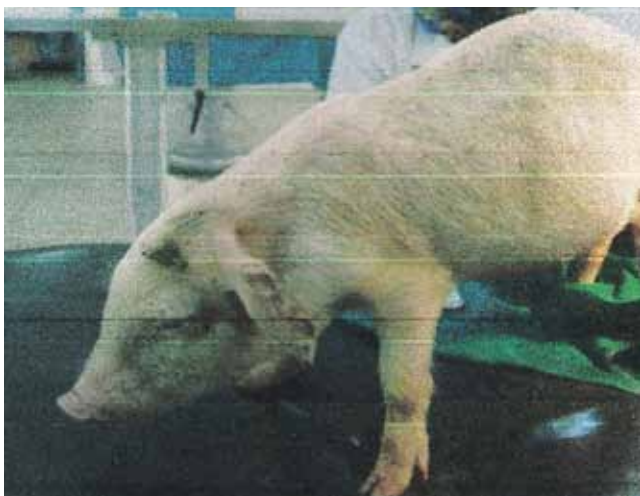


Fig. 5. Piglet after surgery

CASE REPORT

An 8-week-old male piglet from a litter of seven was presented at the Veterinary Teaching Hospital, University of Ibadan, Nigeria, with a complaint of a distended abdomen and unthriftiness compared to his other litter mates. On examination, the abdomen was enlarged, and the anal orifice was absent (Fig. 1 and 2). Auricular temperature was 39.2 °C, heart rate 76 beats per minute, the mucous membrane color was normal, pulse rate 68 beats per minute, respiratory rate 42 breaths per minute and the body weight was 5 kg. A diagnosis of *atresia ani* was made and a surgical option was recommended.

Following a caudal epidural block with a mixture of lignocaine (Lidocaine, Rotexmedica, Germany) and xylazine (Xylazine, Kepro, Holland), the anal area was prepared, and draped for aseptic surgery. An initial incision and deeper exploratory dissection through perineal structures could not establish a link with the rectum (Fig. 3). An option of exploratory laparotomy was therefore considered. The intestine was approached via a ventral midline coeliotomy with an incision made from the umbilicus to the pelvic brim following aseptic

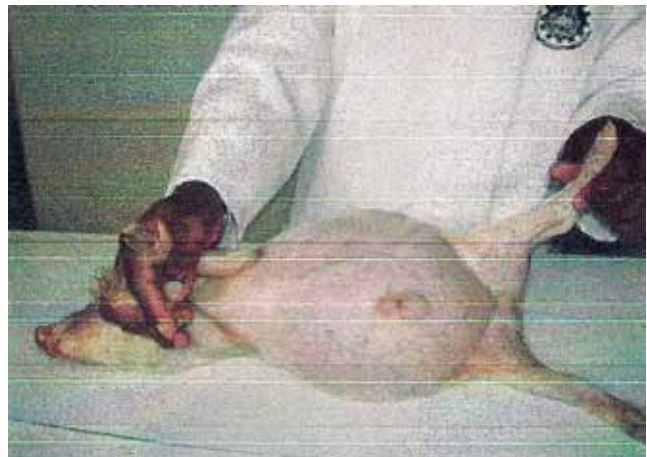


Fig. 2. Piglet showing enlarged abdomen

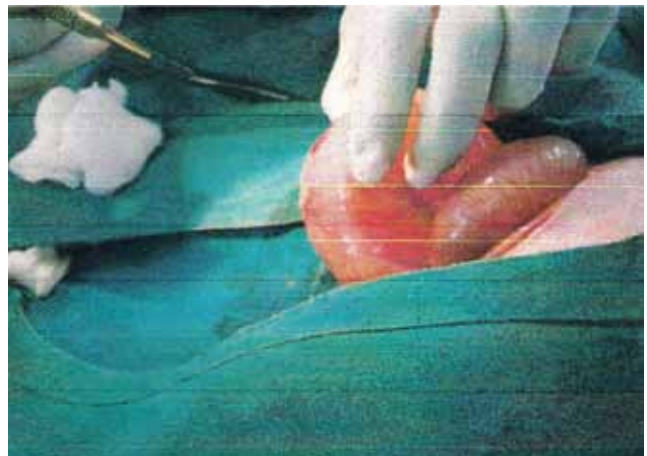


Fig. 4. Exploratory laparotomy and colectomy

preparation. An exploration of the large intestine revealed that the colon ended as a blind sac with an attachment to the pelvic wall. An inserted probe through a colostomy confirmed our observation (Fig. 4). A diagnosis of *atresia ani* and rectum (*atresia ani et rectum*) was made. An anorectal reconstruction was decided against due to a poor prognosis following such a procedure. Following the partial evacuation of the intestine, the abdominal incision was closed routinely in three layers. The piglet recovered smoothly from anaesthesia (Fig. 5). The findings and the implications were communicated to the client who felt satisfied with the surgical effort and took the piglet home.

DISCUSSION

Anorectal malformations are rare in animals. In swine, imperforate anus has been linked with an embryonic developmental defect of the dorsal cloacal plate (2, 8). In the management of this case, an option of radiology was not possible due to lack of x-ray facilities for such species. Besides, the economics of practice could not permit a surgical correction, as the cost of abdominal exposure is twice the estimated cost of the piglet. *Atresia ani* is one of the important causes of intestinal obstruction in the swine species (5). However, because pigs vomit, which help decompress their intestinal tract, the diagnosis of *atresia ani* is sometimes not made until three to four weeks of age (15). This may explain why this piglet could survive until eight weeks before presentation. The incessant vomiting of food and associated discomfort due to filled bowel may have been responsible for the unthriftiness compared with other litter mates.

Atresia ani et rectum is an inheritable sex linked condition which may be associated with the sow or boar (13, 15). Although, the hypothesis on the mode of inheritance of the conditions is still controversial, the observed condition in this piglet may be connected with the uncontrolled inbreeding activities common among pig breeders in this environment. Also, that only this male piglet had this aberration in a litter of seven inconclusively supports the observation of a likely higher incidence in males (10, 15). Although it has also been observed that female piglet with *atresia ani* develop recto-vaginal fistulae which enhances their longevity (6), the survival of this piglet up to 8 weeks has also shown the possibility of longer survival male *atresia ani* piglets when vomiting is not complicated by aspiration and pneumonia.

Mild cases of imperforate anus can be easily managed by surgical opening of the stenosed anus (12). However, more complex cases such as this require a more extensive surgery with intestinal pulling of the pelvic remnant rectum, and anal

reconstruction which is relatively difficult and clouded with a poor prognosis (1). This explained why surgical repair was not undertaken and the patient was discharge to the farmer who probably may have slaughtered the piglet.

REFERENCES

1. Azizi, S., Mohammadi, R., Mohammadpour, I., 2010: Surgical repair and management of congenital intestinal atresia in 68 calves. *Veterinary Surgery*, 39, 115–120.
2. Casaccia, G., Catalano, O. A., Bagolan, P., 2009: Congenital gastrointestinal anomalies in anorectal malformations: What relationship and management. *Congenital Anomalies*, 49, 93–96.
3. Hamori, D., 1962: Über die anlage für brüche bei schweinen. *Zuchthygiene*, 6, 80–84.
4. Henricson, B., 1963: Atresia ani beim schwein. *Acta Vet. Scand.*, 4, 263–269.
5. Hori, T., Giuffra, E., Andersson, L., Ohakawa, H., 2001: Mapping loci causing susceptibility to anal atresia in pigs, using a resource pedigree. *J. Pediatr. Surg.*, 36, 1370–1374.
6. Kimmel, S. G., Mo, R., Hui, C. C., Kim, P. C., 2000: New mouse models of congenital anorectal malformations. *J. Pediatr. Surg.*, 35, 227–231.
7. Kinzelbach, W., 1932: Untersuchungen über atresia ani beim schweine. *Z. Indukt. Abstammungs. Vererbungs.*, 60, 84–124.
8. Kluth, D., Hillen, M., Lambrecht, W., 1995: The principles of normal and abnormal hindgut development. *J. Pediatr. Surg.*, 30, 1143–1147.
9. Lambrecht, W., Lierse, W., 1987: Morphologic studies in swine with anal atresia. *Z. Kinderchir.*, 42, 350–351.
10. Macedo, M., Martins, J. L., Meyer, K. F., 2007: Evaluation of an experimental model for anorectal anomalies induced by ethyl-enethiourea. *Acta Cir. Bras.*, 22, 130–136.
11. Peña, A., Hong, A., 2000: Advances in the management of anorectal malformations. *Am. J. Surg.*, 180, 370–376.
12. Suther, D. N., Chaudhary, S. R., Patel, P. B., Mistry, J. N., Patel, J. B., Nerurkar, S. S., 2010: Surgical management of *atresia ani* in a cow calf. *Veterinary World*, 3, 380–381.
13. Thaller, G., Dempfle, L., Hoeschele, I., 1996: Investigation of the inheritance of birth defects in swine by complex segregation analysis. *J. Anim. Breed. Genet.*, 113, 77–92.
14. Triebler, G., 1984: Zur erbfehlerproblematik beim schwein. *Wiss. Z. Humboldt. Univ.*, 33, 507–510.
15. Wiedemann, S., Fries, R., Thaller, G., 2005: Genome wide scan for anal atresia in swine identifies linkage and association with a chromosome region on *sus scrofa* chromosome 1. *Genetics*, 171, 1207–1217.

Received July 16, 2010



INFLUENCE OF MIDAZOLAM ON SOME ANAESTHETIC INDICES AND SAFETY OF KETAMINE – XYLAZINE COMBINATION IN SWINE

Ajadi, R. A.¹, Adenubi, O. T.², Sogebi, E. A. O.¹

¹Department of Veterinary Medicine and Surgery

²Department of Veterinary Physiology and Pharmacology

University of Agriculture, Abeokuta

Ogun State

ade_vsr@hotmail.com

ABSTRACT

The onset of action (OAN), duration of antinociception (DAN), anaesthesia time (ANT), and recovery time (RCT) were assessed in ten growing pigs (mean weight 17.2 ± 1.62 kg) either receiving intramuscular (i.m.) injections of 10% ketamine (20 mg.kg^{-1}), 2% xylazine (2 mg.kg^{-1}) and 0.1% midazolam (0.25 mg.kg^{-1}) (KXM) or intramuscular injections of ketamine (20 mg.kg^{-1}) and xylazine (2 mg.kg^{-1}) alone (KX) in order to determine the influence of midazolam on ketamine-xylazine combination in pigs. In addition, the heart rates (HR), respiratory rates (RR) and rectal temperatures (RT) were determined immediately after the drug administration and at 10 minutes interval over a period of 60 minutes. Both the OAN and RCT were not significantly different ($P > 0.05$) between the KXM (2.2 ± 0.2 min; 18.6 ± 1.4 min) and the KX (3.0 ± 0.6 ; 23.4 ± 5.0 min), respectively. However, the duration of anaesthesia was significantly longer ($P < 0.05$) in the KXM (92.0 ± 13.6 min) than the KX (54.8 ± 1.6 min). In pigs that received the KXM combination, the DAN was (41.4 ± 12.6 min), while those that received the KX combination showed no evidence of antinociception. The RT was significantly ($P < 0.05$) higher in the KXM anaesthetized pigs than the KX anaesthetized pigs. However, the RR was significantly lower ($P < 0.05$) in the KXM pigs than in the KX anaesthetized pigs. The HR did not differ significantly ($P > 0.05$) between the KXM and the KX anaesthetized pigs. It was therefore concluded, that the 0.25 mg.kg^{-1} i.m. injection of midazolam improved ketamine – xylazine anaesthesia at both the hypnotic and analgesic endpoints.

Key words: anaesthesia; ketamine; midazolam; swine; xylazine

INTRODUCTION

Swine are commonly used in cardiovascular research, nutrition research, organ transplantation studies, reproductive physiology and endocrine function research (13, 14). These studies often require various forms of chemical restraints to ensure humane handling of the animals and provide optimum surgical conditions. In addition, certain conditions may warrant the need for chemical restraints in commercial swine populations. Such conditions include elective castration of growing pigs to improve their carcass quality, caesarian surgery for relief of dystocia in pregnant sows and the detusking procedure in mature boars.

Problems associated with swine anaesthesia include: difficulty in securing venous access for administration of intravenous agents; poor drug absorption from muscle sites due to high fat content; difficulty in tracheal intubation due to laryngospasms; malignant hyperthermia; and lack of efficacy of a single drug or sometimes drug combinations (5). Drug combinations that have been used for anaesthesia in swine include: telazol – ketamine; telazol – xylazine; telazol – ketamine – xylazine; ketamine – xylazine – butorphanol; and ketamine – medetomidine – butorphanol (9, 12). However some of these combinations have not been found to be satisfactory. For instance, the combination of xylazine and ketamine has been reported to have a short-lived duration of anaesthesia (8, 9). On the other hand, the inhalational technique is expensive, may not be feasible in a field condition and a number of volatile anaesthetic agents can precipitate malignant hyperthermia (5).

Ketamine is the most widely used anaesthetics in almost all species including humans, non-human primates, cats, laboratory ro-

dents and wildlife (11). This is so, because the drug is considered to be relatively safe, as it generally causes minimal cardiovascular depression and it may actually stimulate cardiovascular function *via* its sympathomimetic effect (18). In addition, ketamine can be administered intramuscularly as well as intravenously, making it practical for use in animals in which venous access is difficult. Ketamine had been combined with drugs such as xylazine, medetomidine, butorphanol and telazol for chemical restraints, induction of anaesthesia and as total anaesthesia for surgery of short duration in swine so as to counteract the side effects of the other drugs, as well as to improve the quality and duration of the anaesthesia produced (7, 8).

Midazolam is a water soluble benzodiazepine with rapid onset of action due to its rapid uptake from the muscle into the blood stream. Ketamine and midazolam combination have been associated with smooth induction of anaesthesia and a faster recovery time in domestic short-haired cats (1). Although increasing the dosage of xylazine may improve the quality and duration of anaesthesia produced by xylazine combination in pigs, this may however be characterized by the prolonged duration of lateral recumbency and recovery, thus requiring extended monitoring. The addition of midazolam may thus reduce the requirement for xylazine and improve the quality and duration of the anaesthesia produced by xylazine and ketamine combination in pigs. The aim of this study is to determine the influence of a 0.25 mg.kg⁻¹ intramuscular injection of midazolam on the anesthetic properties and safety of xylazine – ketamine combination in growing pigs.

MATERIALS AND METHODS

Ten growing pigs (Niger hybrid and Large White breeds) composed of both sexes and having a mean body weight of 17.2 ± 1.62 kg were used for the study. The pigs were kept in pairs on concrete floored pens. In addition, they were fed with compounded rations consisting of brewery waste, bone meal and groundnut cake, while water was provided *ad libitum*. Prior to the study, all the pigs were assessed to be in good general health based on findings at a complete physical examination which included complete blood counts. The protocol for the study was approved by the Pig Management Committee of the University of Agriculture, Abeokuta.

This study involved a randomized, blinded, cross-over design consisting of ten pigs each. The pigs were anaesthetized twice with either ketamine-xylazine or ketamine-xylazine-midazolam combinations. The time interval between each series was two weeks to allow for the effect of the drug combination to have been washed out. In the first series, the pigs were anaesthetized with intramuscular injection of 20 mg.kg⁻¹ of 10 % ketamine hydrochloride (Ketamine®, Kepro, Holland), 2 mg.kg⁻¹ of 2 % xylazine hydrochloride (xylazine 20 Inj®, Kepro, Holland) and 0.25 mg.kg⁻¹ of 0.1 % midazolam (Dormicum®, Claris life, India) (KXM). In the second series, the pigs were anaesthetized with intramuscular injections of 20 mg.kg⁻¹ of 10 % ketamine hydrochloride and 2 mg.kg⁻¹ of 2 % xylazine hydrochloride (KX). All the pigs were pre-treated with intramuscular injection of atropine sulphate at the rate of 0.04 mg.kg⁻¹ body weight.

Food was withheld for 12 hours prior to induction of anaesthesia; but the pigs were allowed access to water. The pigs were first weighed and then the calculated doses of drugs were injected separately into the gluteal muscles on both hind limbs to induce

anaesthesia. Following the induction of anesthesia, each pig was intubated with a size 6.0 cuffed endotracheal tube and then positioned in lateral recumbency. Antinociception was assessed by the pigs' response to the pain perception from artery forceps applied at the interdigital space. In this study, the onset of drug action (OAN), duration of antinociception (DAN), anaesthesia time (ANT) and recovery time (RCT) were recorded. Onset of action was calculated as the time interval in minutes between the end of drug administration and the time taken for the pig to assume the lateral recumbent position. The duration of antinociception was calculated as the interval in minutes between the disappearance and reappearance of the pedal withdrawal reflex. Anaesthesia time was calculated as the time interval in minutes between the pigs' assumption of lateral recumbency and the return to sternal posture. The recovery time is the time interval in minute between assumption of sternal posture and standing position without ataxia by the pigs.

Also, the pigs' heart rates (HR), respiratory rates (RR), and rectal temperatures (RT) were determined immediately after the induction of anaesthesia (T=0 min) and at ten minutes interval until the pigs assumed sternal position. Heart rates were counted in beats/min with the aid of precordial stethoscope. Respiratory rates were counted in breaths/min by visual observation of chest excursion, while the rectal temperatures were measured in centigrade using a clinical thermometer. In addition, observable adverse effects of drugs such as apnoea, cyanosis, and malignant hyperthermia were noted.

The data were presented as the mean ± standard deviation. Anaesthetic indices were compared using Student paired *t*-test while physiological variables were compared using the analysis of variance (ANOVA) for repeated measures. A *P* < 0.05 was accepted as significant in all cases.

RESULTS

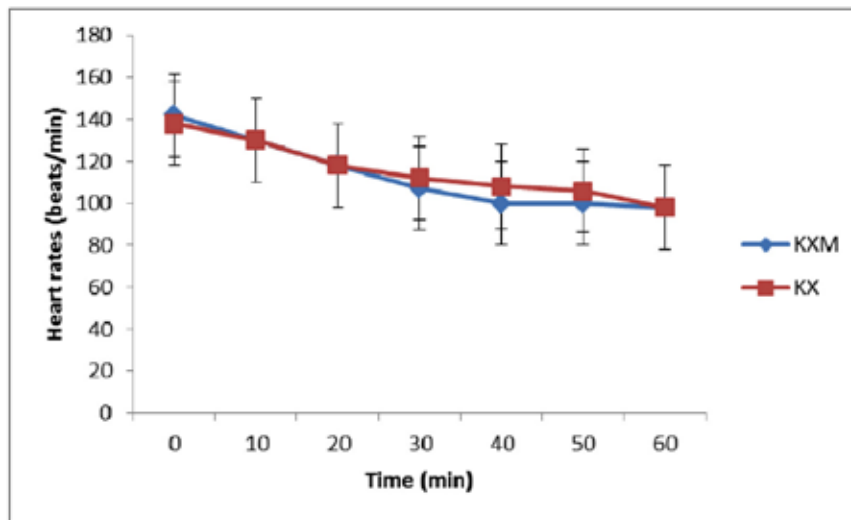
There were no observed adverse effects in either the KXM or the KX anaesthetized pigs. The RT was significantly higher (*P* < 0.05) in the KXM anaesthetized pigs than the KX anaesthetized pigs. However, the RR was significantly lower (*P* < 0.05) in the KXM pigs than the KX anaesthetized pigs. The HR did not differ significantly (*P* > 0.05) between the KXM and the KX anaesthetized pigs (Fig. 1).

Both the OAN and RCT were not significantly different (*P* > 0.05) between the KXM (2.2 ± 0.2 min; 18.6 ± 1.4 min)

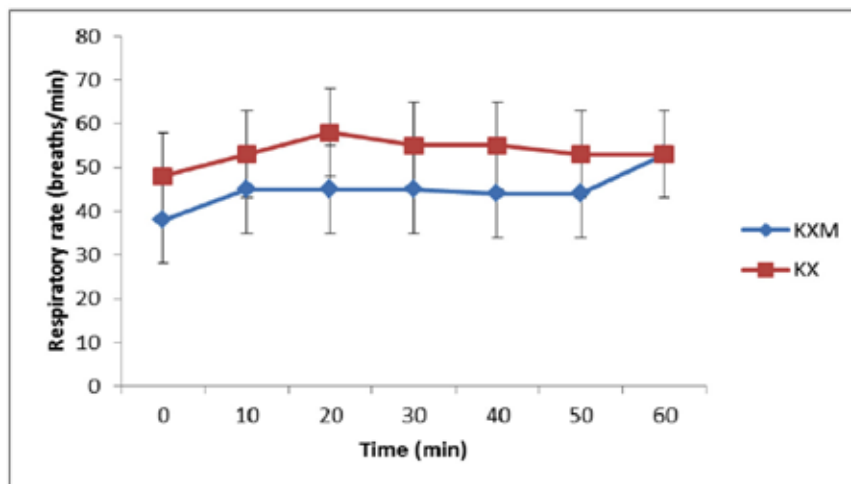
Table 1. Anaesthetic indices following either ketamine – xylazine – midazolam (KXM) or ketamine – xylazine (KX) anesthesia in growing pigs

Anaesthetic indices (min)	KXM n = 10	KX n = 10
Onset of drug action	2.2 ± 0.2	3.0 ± 0.6
Duration of antinociception	41.4 ± 12.6	NIL*
Anaesthesia time	92.0 ± 13.6	54.8 ± 1.6*
Recovery Time	18.6 ± 1.4	23.4 ± 5.0

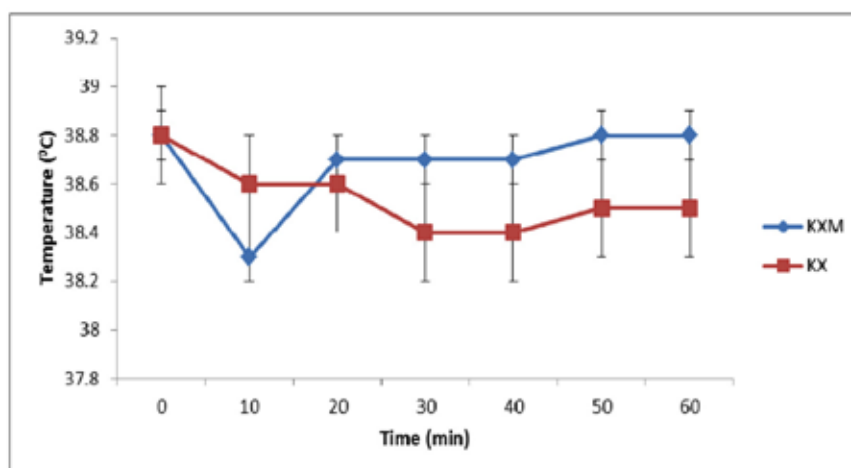
* – *P* < 0.05; K – Dose of ketamine 20 mg.kg⁻¹
X – Dose of xylazine 2 mg.kg⁻¹; M – Dose of midazolam 0.25 mg.kg⁻¹



(a)



(b)



(c)

Fig. 1. Changes in heart rates (a), respiratory rates (b) and rectal temperatures (c) following either ketamine – xylazine – midazolam (KXM) or ketamine – xylazine (KX) anaesthesia in growing pigs

and the KX (3.0 ± 0.6 ; 23.4 ± 5.0 min), respectively. However, the duration of anaesthesia was significantly ($P < 0.05$) longer in the KXM (92.0 ± 13.6 min) than the KX (54.8 ± 1.6 min). The pigs that received the KXM combination had a duration of antinociception of 41.4 ± 12.6 min while there was no evidence of antinociception in the pigs that received the KX combination (Table 1).

DISCUSSION

This is the first study to evaluate the influence of midazolam on the anaesthesia produced by the combination of ketamine and xylazine in pigs. The results of this study showed that both the KXM and the KX combinations were characterized by rapid onset, smooth induction of anaesthesia, and rapid recovery with a virtual lack of adverse reactions.

Both the KXM and the KX combinations were characterized by large volume injection (0.44 ml.kg^{-1} in KX and 0.66 ml.kg^{-1} in KXM). Pain on intramuscular injection is partly due to tension placed on the muscle fibers by large-volume injectants (2). However in this study, the drugs were administered separately on both hind limbs in order to reduce the volume of injectant at each site and consequently minimize pain on injection.

Endotracheal intubation is routinely done to maintain a patent airway and prevent aspiration of gastro-intestinal content in anaesthetized patients. Laryngeal and pharyngeal reflexes are generally well maintained with ketamine, which may impair intubation (6). Xylazine and midazolam have muscle relaxant properties which may improve conditions for intubation in the pigs. In this study, endotracheal intubation was achieved with the aid of paediatric laryngoscope because of the anatomy of the pig's oropharynx. However, the tube was removed after successful intubation since maintenance of anaesthesia is not dependent on it.

One of the major challenges of swine anaesthesia is the difficulty in performing vene punctures. This may limit the use of intravenous drugs thus making the administration of most drugs to be largely intramuscular. However, the uptake of drugs from intramuscular site is dependent on the solubility of the drug in water and the amount of adipose tissue surrounding the muscle, as well as the blood flow to the area. In swine, the large adipose reserves delay uptake of oil-based preparations. This explains why midazolam was preferred over diazepam in this study.

No single anaesthetic agent has been found ideal in providing adequate anaesthesia for surgery in swine. Thus two or more drugs are often combined for the purpose (12, 15). Xylazine and ketamine combinations have been evaluated in pigs (8, 10) and the combination was reported with short-lived duration of analgesia. In this study however, the KX combination was not associated with loss of the pedal withdrawal reflex. This might be associated with the dosage of the drugs used in this study.

The assessment of the rectal temperature during anaesthesia in swine is essential because of the risk of the development of malignant hyperthermia. In this study, the rectal

temperature was higher in the KXM anaesthetized pigs than the KX anaesthetized pigs. This can probably be attributed to the midazolam. Midazolam is known to promote vasodilatation when given by the intramuscular route and this may affect re-distribution of heat during surgery (17). Hypothermia after induction of general anaesthesia results from the re-distribution of body heat from the core to the periphery. Both the central inhibition of tonic thermoregulatory vasoconstriction in arteriovenous and venous dilatation contributes to the distribution (16). Ketamine increases peripheral arteriolar resistance resulting in less core hypothermia. On the other hand, midazolam decreased the core temperature resulting in a re-distribution of heat to the periphery. Since the rectal temperature was assessed in this study, it is logical to assume that the higher rectal temperature in the KXM anaesthetized pigs was due to the midazolam mediated reduction in core body temperature and subsequent re-distribution of the body heat to peripheral structures. This action might be beneficial in the prevention of malignant hyperthermia.

The HR did not differ significantly between the KXM and the KX in the anaesthetized pigs. This finding is similar to earlier observations (9, 10). In both series, HR tended to decrease. Decreases in heart rates have been reported in rabbits anaesthetized with a ketamine – midazolam combination (3). Similarly, it has been shown that the direct application of large doses of midazolam exerted a negative chronotropic effect on the rabbit myocardium (4). One may conclude that the lower heart rates observed in the KXM group may be associated with the negative chronotropic effect of midazolam. Although this change is not statistically significant.

There was no significant difference in both the OAN and RCT between the KXM and the KX combinations in the pigs. This finding is similar to that reported earlier for telazol – ketamine – xylazine, telazol – ketamine and ketamine – xylazine combinations in pigs (10). This finding suggests that the KXM combination does not adversely affect the duration of recumbency in the anaesthetized pigs. Finally, the addition of 0.25 mg.kg^{-1} of midazolam was found to increase significantly the duration of anaesthesia as well as the duration of antinociception of the ketamine – xylazine anaesthesia in pigs. This finding suggested that midazolam may be additive to the ketamine – xylazine combination at both hypnotic and analgesic endpoints.

In conclusion, the KXM combination is characterized by rapid onset, smooth induction and recovery, with moderate duration of analgesia and a virtual lack of notable adverse effects. It is therefore recommended for surgery of short duration in growing pigs.

REFERENCES

1. Ajadi, R. A., Agbesinu, A. J. B., Adetunji, A., Akinrinmade, J. F., 2007: A trial of propofol and ketamine combination in domestic short-haired cats. *Folia Veterinaria*, 51, 30–33.
2. Diehl, K. H., Hull, R., Morton, D., 2001: A good practice guide to the administration of substances and removal of blood, including routes and volumes. *J. Appl. Toxicol.*, 21, 15–23.

3. Dupras, J., Vachon, P., Cuveliez, S., 2001: Anaesthesia of the New Zealand rabbit using the combination of tiletamine – zolazepam and ketamine – midazolam with or without xylazine. *Canadian Veterinary Journal*, 42, 455–460.
4. Grint, N.J., Murison, P.J., 2008: A comparison of ketamine- midazolam, ketamine- medetomidine combinations for induction of anaesthesia in rabbits. *Veterinary Anaesthesia and Analgesia*, 35, 113–121.
5. Hall, L.W., Clark, K.W., 1991: *Veterinary Anesthesia*, 9th edn., Balliere Tindall, London, 52–54.
6. Hedenqvist, P., Roughan, J.V., Orr, H.E., Antunes, L.M., 2001: Assessment of ketamine/medetomidine anaesthesia in the New Zealand White Rabbit. *Veterinary Anaesthesia and Analgesia*, 28, 18–24.
7. Heinonen, L.M., Raekallio, R.M., Oliviero, C., Ahokas, S., Peltoniemi, O.A., 2009: Comparison of azaperone – detomidine – butorphanol – ketamine and azaperone – tiletamine – zolazepam for anaesthesia in piglets. *Veterinary Anaesthesia and Analgesia*, 36, 151–157.
8. Kim, M.J., Park, C.S., Jun, M.H., Kim, M.C., 2007: Antagonistic effects of yohimbine in pigs anaesthetized with tiletamine/zolazepam and xylazine. *Vet. Rec.*, 161, 620–624.
9. Ko, J.C., Williams, B.L., Smith, V.L., McGrath, C.J., Jacobson, J.D., 1993: Comparison of telazol, telazol-ketamine, telazol-xylazine and telazol-ketamine-xylazine chemical restraint and anaesthetic induction in swine. *Lab. Anim. Sci.*, 43, 476–480.
10. Ko, J.C., Williams, B.L., Rogers, E.R., Pablo, L.S., McCaine, W.C., McGrath, C.J., 1995: Increasing xylazine dose enhanced anaesthetic properties of telazol- xylazine combination in swine. *Lab. Anim. Sci.*, 45, 290–294.
11. Lin, H.C., 1996: Dissociative anesthetics. In Thurmon, J.C., Tranquilli, W.J., Benson, G.J. (Eds.): *Lumb and Jones Veterinary Anesthesia*, 3rd edn., Williams & Wilkins Co., Baltimore, 241–296.
12. Sakaguchi, M., Nishimura, R., Sasaki, N., Ishiguro, T., 1996: Anaesthesia induced in pigs by use of a combination of medetomidine, butorphanol and ketamine and its reversal by administration of atipemazole. *Am. J. Vet. Res.*, 57, 529–534.
13. Shawley, R., 1994: Large Animal Anaesthesia. *AWTC*, 5, Special Issue: Farm animals in research and teaching, 1–8.
14. Swindle, M.M., 1992: Anaesthesia in Swine and Swine Biomedical Research. *Iowa State University Press*, 312 pp.
15. Sweitzer, R.A., Ghneim, G.S., Gardner, I.A., Van Vuren, D., Gonzales, B.J., Boyce, W.M., 1997: Immobilization and physiological parameters associated with chemical restraint of wild pigs with telazol and xylazine hydrochloride. *J. Wildl. Dis.*, 33, 198–205.
16. Takehido, I., Tomiei, K., Dannel, S., Sumiko, T., Kazuya, N., Chiaki, S., Shigehito, S., 2001: Ketamine reduces the magnitude of redistribution hypothermia. *Anaesthesia and Analgesia*, 93, 934–938.
17. Toyota, K., Sakura, S., Saito, Y., Ozasa, H., Uchida, H., 2004: Effect of pre-operative administration of midazolam on the development of intra-operative hypothermia. *Anaesthesia*, 59, 116–121.
18. Wagner, A.E., Helleyer, P.W., 2000: Survey of anesthetic techniques and concerns in private veterinary practice. *J. Am. Vet. Med. Assoc.*, 217, 1652–1657.

Received July 11, 2011



EFFECT OF XENOBIOTICS ON THE STRUCTURE OF THE RABBIT'S LIVER

Holovská, K. jr., Almášiová, V., Tarabová, L., Cigánková, V.

Department of Anatomy, Histology and Physiology
University of Veterinary Medicine and Pharmacy, Košice
The Slovak Republic

kholovska@uvmf.sk

ABSTRACT

The liver is a multifunctional organ that plays an essential role in detoxification. In this study we investigated the effect of bendiocarbamate on the structure of this organ. Bendiocarb (2,2-dimethyl-1,3-benzodioxol-4-yl-N-methyl carbamate) is a carbamate insecticide. In agriculture, it is used against a variety of insects, especially those found in the soil. The morphological changes in the rabbit's liver were observed by light microscopy on days 3 and 10 after exposure to bendiocarb. On day 3 of the experiment we observed a massive infiltration of leukocytes into the portal spaces. In some cases the inflammatory cells extended from the portal tract into the parenchyma. On day 10 of the experiment, the morphological changes in the liver were not uniform. The affected lobules contained focal inflammation, with necrotic hepatocytes. Some of hepatocytes within the lobules lost their structure. The most common feature was binucleated hepatocytes.

Key words: bendiocarbamate; light microscopy; liver; rabbit

INTRODUCTION

Pesticides are biologically active chemicals, which have been thoroughly tested for safety and usefulness before they are released for agricultural use. However, if misused, they may be harmful to humans, other animals and the environment. Bendiocarbamate (bendiocarb, 2,2-dimethyl-1,3-benzodioxol-4-yl-N-methyl carbamate) is a carbamate insecticide. In agriculture, it is used against a variety of insects, especially those found in the soil. Like other carbamate insecticides, bendiocarb kills insects and causes poisoning in ani-

mals by inhibiting the enzyme acetylcholinesterase, which normally functions to degrade acetylcholine in nerve synapses (1, 2, 7). Bendiocarb is moderately toxic. It is well known that there is comparatively a low risk of carbamates for mammals which is based on their biodegradation.

The liver has the primary function of detoxification which takes place within the hepatocytes. The hepatic parenchyma consists of hepatocytes and a large proportion of nonparenchymal cells, including sinusoidal endothelial cells, Ito cells and Kupffer cells. Kupffer cells are resident macrophages of the liver which play an important role in its normal physiology and homeostasis. They are the first cell population that comes into contact with the bacteria, bacterial endotoxins, microbial debris and different xenobiotics from the gastrointestinal tract, which are transported to the liver *via* the portal vein (4). Because the liver plays a central role in transforming and clearing chemicals and is susceptible to the toxicity from these agents, the aim of our study was to observe the morphological changes in the liver produced by this insecticide.

MATERIALS AND METHODS

Animals and diet

The experiment was carried out on 18 rabbits (9 males, 9 females), 54-day old, hybrid Hyla-27, mean weight 2.0 ± 0.20 kg. The clinically healthy rabbits were kept in a well ventilated environment and received a standard diet Norm-type-0-10 (BIOFER r. č. 7313/A) and water *ad libitum*. The animals were divided into three groups, six animals in each (control, days 3 and 10 of administration). The first group was the control group without any treatment. Rabbits in all experimental groups ($n=6$) were administered ben-

diocarb (96 % Bendiocarb, Bayer) perorally at a dose of 5 mg.kg⁻¹ per day in capsules (LD50 = 35–40 mg.kg⁻¹). The rabbits from both the experimental groups and control group were euthanatized on days 3 and 10 of the experiment (8). Animals from all experimental groups were healthy and their condition was judged as good at the commencement of the experiment. The conditions of the animals, their manipulations and use corresponded with the requirements of the ethical commission.

Light microscopy (LM)

Histological samples of hepatocytes for LM were processed by a commonly recognized histological technique. They were fixed in 4 % neutral formaldehyde and embedded in paraffin. Then, 5–7 µm thick slides were stained with hematoxylin and eosin and photographed under a light microscope (Jenamed).

RESULTS

In the control group, the liver parenchyma morphology was normal. The hepatocytes were arranged in the anastomosing cords around the central vein. Cords were surrounded by irregular sinusoids, lined by endothelial and Kupffer cells. Large, euchromatic nuclei with prominent nucleoli were located in the centre of the hepatocytes. Occasionally, binucleated cells were observed. The portal spaces, located at the periphery of the lobules, contained interlobular vein, artery and the bile duct. The lobules were separated by small amounts of connective tissue.

On day 3 of the experiment, marked changes in the portal spaces were observed. These spaces were enlarged and inflammatory cells were accumulated within them. The interlobular bile ducts contained intraepithelial lymphocytes. Hepatocytes around the portal spaces were usually intact. Some cells contained small lipid droplets. In some case, the inflammatory cells in-

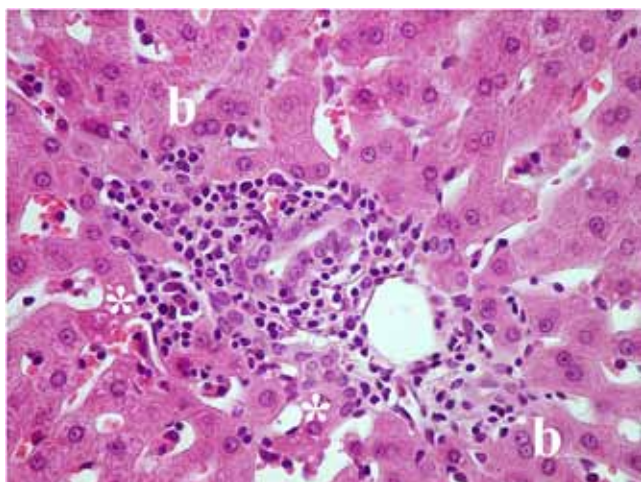


Fig. 1. Interlobular areas on day 3 of the experiment (H-E). Magn. × 400
*—lipid droplets; b—binucleated hepatocytes

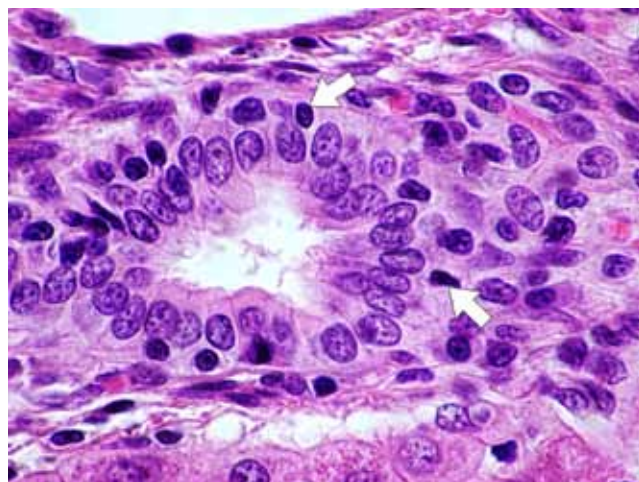


Fig. 2. Day 3 of the experiment (H-E). Magn. × 1000
Interlobular bile duct with intraepithelial lymphocytes — arrows

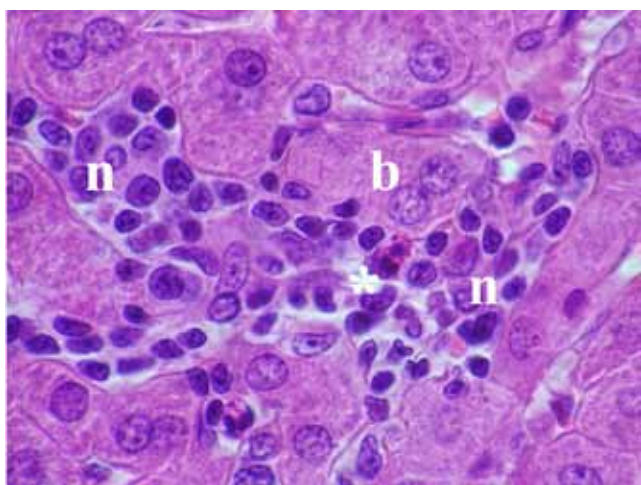


Fig. 3. Interlobular areas on day 10 of the experiment (H-E).
Magn. × 1000
*—granulocyte; b—binucleated hepatocyte; n—necrotic hepatocyte

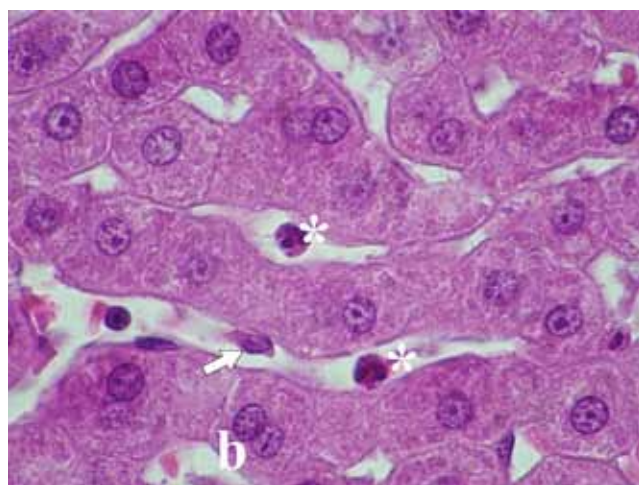


Fig. 4. Parenchymal area on day 10 of the experiment (H-E).
Magn. × 1000
arrow—Kupffer cell; b—binucleated hepatocytes; *—granulocytes

filtrate extended from the portal spaces into the parenchyma. Within the hepatic lobules, scattered necrotic single cells were observed. The nuclei of these cells displayed clumping of the chromatin along the nuclear membrane. The nuclei were smaller and stained deeply basophilic. The lobules were diffusely infiltrated with leucocytes and individual necrotic hepatocytes were also surrounded by them. The regenerative features, such as binucleated hepatocytes, were common (Fig. 1, 2).

Morphological changes were observed also in the liver parenchyma on day 10 of the experiment. The changes were not uniform throughout the liver. Many lobules had normal structure and were situated next to affected ones. The affected lobules contained foci of lymphocytes and granulocytes. Hepatocytes within these foci were altered and their cytoplasm was pale, homogenous, with unclear deformed nuclei. The foci were surrounded by binucleated cells. Some of them contained small lipid droplets. Prominent Kupffer cells were present in the sinusoids. Occasionally the portal spaces were infiltrated by lymphocytes but in smaller numbers compared to day 3 of the study. The hepatic regeneration was reflected in the presence of many binucleated hepatocytes (Fig. 3, 4).

DISCUSSION

The major metabolic pathway for bendiocarb is hydrolysis to the methyl carbamate and heterocyclic compound (2,2-dimethyl-1,3-benzodioxol-4-ol), or oxidation to other heterocyclic compounds (N-hydroxymethylbendiocarb and 5,8- or 7-hydroxybendiocarb). The rate of degradation is pH-dependent. It is rapid in alkaline media and slower in neutral and acidic media. Bendiocarb and its degradation metabolites can form glucuronide and sulphate conjugates. Undoubtedly, there are also other metabolic pathways, since low levels of unidentified conjugates and non-conjugated metabolites have been known to occur. Metabolic activity or biotransformation does not necessarily result in less toxic compounds. It is well known that toxic effects can be modified by other substances. The ratio of the various metabolites and degradation products varied considerably, depending on many factors, e.g. on the dose of bendiocarb, type and interval of application, sensitivity of the organisms to a subsequent exposure, environmental degradation or metabolism in plants (2).

Generally carbamates are excreted rapidly and do not accumulate in mammalian tissues. Although they are excreted, their toxic effect lies in the cumulative effect of all their metabolites. Sharma (12) recorded an increase in the activities of transaminases and acid phosphatases suggesting hepatocellular damage. In contrast, Singh and Tripathi (13) reported a significant inhibition of the liver enzymes including acid and alkaline phosphatases. The activities of antioxidant enzymes (AOE) were significantly changed in both experimental groups on days 3 and 10 of this experiment (15). These changes indicated an increased concentration of reactive oxygen species (ROS) and a toxic effect of bendiocarbamate on the metabolism of the animals.

We also observed toxic effect of bendiocarb on the structure of liver. The alteration was not observed in the entire

parenchyma uniformly. The most affected areas showed focal necrosis with leucocytes inflammation. Hepatocytes within these areas were changed. Their cytoplasm was pale, homogenous, with lightly stained and irregular nuclei. These foci were surrounded by unchanged hepatocytes. Some hepatocytes at the periphery were binucleated, which may be a regenerative attempt to replace altered-damaged cells. Also, prominent Kupffer cells were present in the sinusoids. The hepatocellular stress induced by hepatotoxins may lead to activation of these liver resident macrophages. Activated cells release cytokines. These cytokines are released by natural killer cells as well as by Kupffer cells (10). Kupffer cells play a central role in the hepatic response to toxic agents. Their topological position within the liver sinusoid makes the Kupffer cells the first macrophages to come into contact with foreign materials that enter the circulation by the way of the portal vein. The activation of Kupffer cells results in the release of an array of inflammatory mediators, growth factors, and reactive oxygen species (6, 11, 14). While excess ROS are able to cause cell destruction by massive lipid peroxidation, the release of ROS at low concentrations are important cytotoxic and signalling mediators in the pathophysiology of inflammatory liver diseases and also induce hepatocyte cell regeneration (5). The activation of Kupffer cells is necessary for the optimal regenerative ability of the liver, which is a very complex phenomenon (4, 9).

The liver often encounters oxidative stress which affects its function, induces hepatocyte cell death and disturbs the regeneration process after injury. Therefore tight regulation of the cellular redox balance in the liver is essential (3). Despite the fact that AOE were changed (15) and parenchyma contained more of less altered-damaged areas, we observed signs of regeneration, which was reflected in the presence of many binucleated hepatocytes. Probably the cytokines released from Kupffer cells constitute a survival signal, protecting hepatocytes from cell death and in some cases stimulating their proliferation (11)

CONCLUSION

In our study we observed the toxic effect of the bendiocarbamate on the structure of the liver parenchyma. Bendiocarb induced various morphological changes. The most pronounced change on day 3 of the experiment was massive accumulation of inflammatory cells within the portal spaces. The morphological changes observed on day 10 were different and consisted of focal necrosis within the lobules. These foci were surrounded by binucleated cells, which demonstrated that the liver has the capacity to regenerate after toxic injury.

REFERENCES

1. Lešník, F., Danko, J., 2005: Xenobiotics in relation to health. In Danko, J., Lešník, F., Jenča, A. *et al.*: *Xenobiotics in Relation to Health* (In Slovak). University of Veterinary Medicine, Košice, 7–12.

2. Bendiocarb, C. O., 1982: Pesticide residues in food: evaluations, file: //E:\Lymfatic\legath\carbamates\bendiocarb.htm
3. Beyer, T. A., Xu, W., Teupser, D., Keller, U., Bugnon, P., Hildt, E. *et al.*, 2008: Impaired liver regeneration in Nrf2 knockout mice: role of ROS-mediated insulin/IGF-1 resistance. *The EMBO Journal*, 27, 212–223.
4. Bilzer, M., Roggel, F., Gerbes, A. L., 2006: Role of Kupffer cells in host defence and liver disease. *Liver International*, 26, 1175–1186.
5. Jaeschke, H., 2000: Reactive oxygen and mechanisms of inflammatory liver injury. *Journal of Gastroenterology and Hepatology*, 15, 718–724.
6. Mahli, H., Gores, G. J., Lemasters, J. J., 2006: Apoptosis and necrosis in the liver. A Tale of two deaths? *Hepatology*, 43, 531–544.
7. Petrovová, E., Luptáková, L., Vdoviaková, K., Maženský, D., 2010a: Bendiocarb embryotoxicity on the chick development from stage 20. *Folia Veterinaria*, 54, 46–50.
8. Petrovová, E., Maženský, D., Vdoviaková, K., Luptáková, L., 2010b: Changes in the structure of rabbit lymph nodes after bendiocarb administration (In Slovak). *Martinský morfológický zborník* (Martin Morphological Proceedings), 76–78.
9. Michalopoulos, G. K., 2007: Liver regeneration. *J. Cell Physiology*, 213, 28–300.
10. Ramadori, G., Moricovi, F., Malik, I., Dudas, J., 2008: Physiology and pathophysiology of liver inflammation damage and repair, http://www.jpp.krakow.pl/journal/archive/0808_s1/articles/05_article.html
11. Roberts, R. A., Ganey, P. E., Ju, C., Kamendulis, L. M., Rusy, I., Klauni, J. E., 2007: Role of the Kupffer cell in mediating hepatic toxicity and carcinogenesis. *Toxicol. Sci.*, 96, 2–15.
12. Sharma, B., 1999: Effect of carbaryl on some biochemical constituents of blood and liver of *Clarias batrachus*, a fresh-water teleost. *J. Toxicol. Sci.*, 3, 157–164.
13. Singh, S. K., Tripathi, P. K., Zadav, R. P., Singh, D., Singh, A., 2004: Toxicity of malathion and carbaryl pesticides: effects of some biochemical profiles of the fresh water fish *colisa fasciatis*. *Bull. Environ. Contam. Toxicol.*, 72, 592–599.
14. Schwabe, F. R., Brenner, D. A., 2006: Mechanisms of Liver Injury. I. TNF- α -induced liver injury: role of IKK, JNK, and ROS pathways. *Am. J. Physiol. Gastrointest. Liver Physiol.*, 290, 583–589.
15. Sobeková, A., Holovská, K., Lenártová, V., Flešárová, S., Javorský, P., 2009: The another toxic effect of carbamate insecticides. *Acta Biologica Hungarica*, 60, 45–54.

Received February 24, 2011



BENEFICIAL EFFECTS OF THIAMINE, ASCORBIC ACID, AND ITS COMBINATION ON PARAQUAT TOXICITY IN RATS

Akinloye, O. A., Adeniyi, T. T., Adamson, I.

Department of Biochemistry, College of Natural Sciences, University of Agriculture,
P. M. B. 2240, Abeokuta
Nigeria

oaakin@yahoo.com.

ttadeniyi@yahoo.com

ABSTRACT

We have examined the beneficial effects of thiamine, ascorbic acid and its combination on the tissue defense system in paraquat-induced oxidatively stressed rats. In the group of rats treated with paraquat alone, the levels of lipid peroxidation, as measured by the concentration of malondialdehyde (MDA) as well as the activities of antioxidant enzymes, were found to be increased significantly ($P < 0.05$). Treatments with thiamine, ascorbic acid and its combination resulted in a significant ($P < 0.05$) fall in the level of MDA, accompanied with increased catalase, superoxide dismutase and glutathione peroxidase activities. In fact, combination of both vitamins at the highest concentrations (vitamin C = $900 \text{ mg.kg}^{-1} \text{ b. w.}$; vitamin B_1 = $\text{mg.kg}^{-1} \text{ b. w.}$) had no synergistic effect as observed by the level of MDA. The results suggest that some alterations/modulations associated with paraquat toxicity could be ameliorated by treatments with vitamins either singly or in combination at moderate concentrations.

Key words: ascorbic acid; paraquat; rats; thiamine

INTRODUCTION

Paraquat-induced oxidative stress in blood and some tissues has been postulated to be responsible for the possible observable mechanisms of paraquat (PQ) toxic effects (2). Disruption of the pro-oxidant/anti-oxidant balance is also known to lead to tissue injury. It was reported that exposure to PQ often leads to an increased level

of lipid peroxidation and also altered the antioxidant defense system (3). Much of these effects have been known to be much more pronounced in the lung. However, other tissues and organs could not be said to be totally free from the toxic effects of this chemical. A number of recent studies confirmed the possible involvement of reactive-oxygen species (ROS) in PQ-induced toxicity (9, 10).

Many antioxidant molecules have been used to evaluate PQ-induced oxidative damage in animals and human studies (17). Reduced glutathione concentrations as well as modifications in superoxide dismutase activity are parts of the frequently used markers in the tissues or in the blood. Based on the fact that free radicals used to be generated during the pathogenic processes induced by PQ, it was therefore presumed that supplementation of antioxidants could be an alternative method for detoxification/ameliorating therapy. Specifically, ascorbic acid, with antioxidant features has been well reported with the capability of protecting cells from oxidative stress (13, 15, 20). Thiamine, an endogenous sulphhydryl (-SH) containing molecule was recognized as one of the protective agent for lead exposure (19). An additional investigation confirmed that the simultaneous administration of thiamine (vitamin B_1) and ascorbic acid (vitamin C) together is efficient in protecting or treating the experimental lead intoxication than either of them individually (20).

The investigations on the protective effects of vitamins C and B_1 against oxidative induced stress were fairly well defined and documented. This study was therefore conducted to investigate whether synergistic combinations of vitamin C and vitamin B_1 at graded concentrations would be able to protect the rats' tissues defense system against PQ-associated oxidative stress.

MATERIALS AND METHODS

Animals and Experimental Design

Rats used were purchased from the Department of Veterinary Anatomy, University of Agriculture, Abeokuta. They were housed in plastic-wired cages in the laboratory animal house, with 12 hour dark/light cycles at the temperature of 20–25 °C and relative humidity of 40–70%. Rats were provided with standard rat feeds (Vital feed Ltd, Nigeria) and water *ad libitum*. They were allowed to acclimatize for a week after which they were assigned into eleven groups (n=7). Rats in group I served as a control and received tap water alone. Rats in group II received 0.1 mM PQ (stock 276 g.l⁻¹ paraquat dichloride solution, Gramoxone® super, manufactured by Syngenta Crop Protection AG Basle, Switzerland) alone in drinking water, rats in groups III–XI were post-treated with different doses of vitamin C (100, 300, 900 mg.kg⁻¹ b.w.) and vitamin B₁ (10, 30, 90 mg.kg⁻¹ b.w.) after exposure to PQ according to 3X3 factorial design using oral gavages daily as shown in Table 1. Vitamins B₁ and C were products of Kunimed Pharmachem Ltd. 1, Adelanwa Street, Valley Estate, Dopemu, Ikeja, Lagos, Nigeria. Each tablet contains 100 mg thiamine and ascorbic acid respectively.

Table 1. The dose of paraquat and vitamins administered to different groups of rats

Group	Paraquat [mM]	Vitamin C [mg.kg ⁻¹]	Vitamin B ₁ [mg.kg ⁻¹]
I	0	0	0
II	0.1	0	0
III	0.1	100	10
IV	0.1	100	30
V	0.1	100	90
VI	0.1	300	10
VII	0.1	300	30
VIII	0.1	300	90
IX	0.1	900	10
X	0.1	900	30
XI	0.1	900	90

All experimental animals were under the described treatments for two weeks. At the end of the treatment, blood samples were collected by cardiac puncture into heparinized tubes, animals were dissected and the liver excised and then stored in the refrigerator at 4 °C prior to analysis.

Biochemical analysis

The catalase (CAT) activity was measured spectrophotometrically following the method of Aebi (1) and was expressed as the

amount of enzyme that catalyses the decomposition of 1 µmol of H₂O₂ per min. Superoxide dismutase (SOD) activity was determined according to the procedure described by Das *et al.* (4). One unit of SOD activity was defined as the amount of enzyme capable of inhibiting 50% of nitrite formation under assay conditions. The glutathione peroxidase (GSH-Px) activity in the blood erythrocyte haemolysates was measured by the method of Paglia and Valentine (14) with the t-butyl hydroperoxide as the substrate. The enzyme activity was expressed in international units per milligram protein.

Assay of GSH content in the liver was carried out according to the method of Meng and Bai (11) as described by Wang *et al.* (20). Briefly, 0.5 g liver was trimmed in ice cold saline (0.9% w/v NaCl) and gently homogenized in cold 0.1 M phosphate buffer (pH 7.4). The homogenate was filtered through a muslin cloth and was centrifuged at 10,000g for 30 min and the glutathione (GSH, reduced form) was measured in de-proteinised supernatant fraction by using 0.04% 5,51-dithiobis (2-nitrobenzene) (DTNB) in 10% sodium citrate and absorbance was taken at 412 nm. The ex-

Table 2. Changes in blood CAT, SOD, GSH-Px and liver GSH and MDA levels in rats

Group	CAT [U.mg ⁻¹ protein]	SOD [U.mg ⁻¹ protein]	GSH-Px [U.mg ⁻¹ protein]	GSH in liver [µg.100mg ⁻¹ b. w.]	MDA [nmol. mg ⁻¹]
I	10.04 ± 1.2a	6.61 ± 1.83c	100.1 ± 23.1a	244.7 ± 26.5a	0.82 ± 0.03a
II	13.73 ± 2.4b	11.87 ± 1.51b	123.6 ± 18.4b	170.4 ± 21.2b	3.41 ± 0.05b
III	9.83 ± 1.1a	8.71 ± 1.7a	99.34 ± 25.6a	178.6 ± 20.3b	1.06 ± 0.02a
IV	10.2 ± 1.2a	8.33 ± 2.10a	92.82 ± 24.4c	185.3 ± 25.5c	1.09 ± 0.02a
V	8.97 ± 1.1a	9.74 ± 1.81a	95.95 ± 23.1a	217.4 ± 20.3a	1.10 ± 0.03a
VI	11.73 ± 2.0c	9.2 ± 1.63a	94.86 ± 20.2c	205.3 ± 19.7a	1.06 ± 0.01a
VII	10.91 ± 2.3ac	9.01 ± 2.01a	91.00 ± 22.1c	198.3 ± 23.1c	1.41 ± 0.03a
VIII	11.43 ± 2.3c	8.45 ± 2.03a	94.08 ± 22.0c	218.9 ± 21.1a	0.98 ± 0.02a
IX	10.51 ± 1.6a	9.07 ± 1.90a	92.00 ± 24.0c	187.4 ± 25.6c	1.13 ± 0.02a
X	10.63 ± 1.8a	9.63 ± 1.73a	90.08 ± 23.1c	183.2 ± 27.1c	1.02 ± 0.03a
XI	10.1 ± 2.0a	8.80 ± 1.90a	101.0 ± 20.4a	220.0 ± 28.2a	0.85 ± 0.03a

Values are expressed as mean ± SD; n = 7; values with different superscript along the same column were significantly different at P < 0.05

tent of lipid peroxidation in the liver was determined by measuring the amount of malondialdehyde (MDA) formed according to the method of Ohkawa *et al.* (12).

Statistical analysis

Data generated were subjected to statistical analysis. Values were expressed as mean \pm SD. The level of homogeneity among the groups was tested using Analysis of Variance (ANOVA). Where heterogeneity occurred, the groups were separated by Duncan Multiple Range Test (DMRT). All analysis was done using the statistical package for social science (SPSS).

RESULTS

The results of the changes in blood CAT, SOD, GSH-Px and liver GSH and MDA levels in rats are presented in Table 2. It was observed that ingestion of paraquat alone (Group II) resulted in a significant ($P < 0.05$) increase in blood CAT, SOD and GSH-Px activities when compared to the other groups. There was no significant difference in the CAT activities among the treated groups when compared to the control. The SOD activities were found to be least in group I and highest in group II. The combined treatments, at the highest doses in group XI were able to bring the GSH-Px activity near the control value. Group II rats also had the least and highest levels of GSH and MDA respectively. However, supplementation with vitamin C and vitamin B₁ was able to reverse this and bring the values in other groups near that of the control.

DISCUSSION

Paraquat poisoning has been one of the major concerns of the environmentalists especially with respect to those that were occupationally exposed to it. One of the ways by which paraquat exerts its toxic effects is through oxidative stress that may be a crucial contributor to the negative pathogenesis observed after PQ exposure. This study clearly revealed that chronic ingestion of PQ results in a significant increase in blood CAT, SOD and GSH-Px activities while the liver GSH levels were found to decrease. This could be as a result of the generation of free radicals by paraquat in which the enzymes were trying to detoxify. The observed enhanced MDA level in group II rats was not surprising because of the known ability of PQ to initiate and enhance lipid peroxidation.

Under normal physiologic conditions, cells possess enzymatic and non-enzymatic defense systems such as GSH, SOD and CAT, to cope with endogenous free radicals (16). Oxidative stress therefore may occur when antioxidant potential is decreased and/or when oxidative stress is increased. Some researchers had indicated that PQ exposure increased the production of ROS, especially in the lung and liver (6, 8). Kang *et al.* (7) also reported that PQ exposure is indeed associated with a significant increase in lipid peroxide level in the liver. Interestingly, in our study, co-administration of vitamins C and B₁ was able to normalize to a certain level, the PQ toxicity. The observed low level of GSH in group II rats could be

attributed to oxidation of the GSH by reactive oxygen species generated by PQ. However, the vitamin treatments seem to be able to reverse PQ-induced decreases in the GSH level.

GSH is considered to be the first line of defense against oxidative damage and free radical generation, where GSH functions not only as a scavenger but also as a co-factor in metabolite detoxification of ROS (18). Therefore, thiamine with thiol group (-SH) could be presumed to be able to reduce oxidized glutathione (GSSH), thereby making the reduced form more available to scavenge free radicals. Thus, PQ-exposed rats treated with a combination of these vitamins would possess the ability to directly react with lipid hydroperoxides, leading to increased GSH and thereby preventing liver destruction.

It was observed that at the highest dose of ascorbic acid and thiamine, the result differed a bit from the low and middle doses. When compared with the only PQ exposure group, the combination of highest doses vitamin C (900 mg.kg⁻¹) and thiamine (90 mg.kg⁻¹) had no significant or observable effect on PQ toxicity or oxidative damage. The possible reason for this could be due to the ability of vitamin C to act as pro-oxidant especially at higher or excessive concentrations. The pro-oxidant character was due to its high reactivity with iron (5). Moreover, thiamine has been assumed to be generally non-toxic mainly due to its easy and readily excretion of excess from the body. In addition, in most multi-vitamin supplements for human and mice that were commercially available, 90–100 mg or more of thiamine per kg or body weight were usually added for everyday intake (21).

Thus, we thought that the combination of vitamin C and thiamine did not produce synergistic effects at the tested concentrations. Further work is in progress as to what extent do these vitamin combinations confer protections at the cellular level.

REFERENCES

1. Aebi, H., 1983: Catalase. In Bergmeyer, H.: *Methods of Enzymatic Analysis*. Verlag Chemical, Weinheim, 273 pp.
2. Banerjee, B.D., Seth, V., Ahmed, R. S., 2001: Pesticide-induced oxidative stress: Perspective and trends. *Rev. Environ. Hlth.*, 16, 1–40.
3. Bismuth, C., Gamier, R., Dally, S., Fournier, P.E., Siherrmann, J.M., 1982: Prognosis and treatment of paraquat poisoning. A review of 28 cases. *J. Clin. Toxicol.*, 19, 461–474.
4. Das, K., Samanta, L., Caning, G.B.N., 2000: A modified spectrophotometric assay for superoxide dismutase using nitrite formation by superoxide radicals. *Ind. J. Biochem. Biophys.*, 37, 201–204.
5. Halliwell, B., Gutteridge, J., 1990: *Free Radicals in Biology and Medicine*. Clarendon Press, New York, 25–27.
6. Igarashi, K., Kimura, Y., Takenaka, A., 2000: Preventive effect of dietary acylated anthocyanins on PQ induced oxidative stress in rats. *Biosci. Biotechnol. Biochem.*, 64, 1600–1607.
7. Kang, S.A., Yang, Y.J., Park, H., 1998: *In vivo* dual effect of vitamin C on paraquat induced lung damage. *Free Rad. Rev.*, 28, 93–107.

8. Kimura, Y., Araki, Y., Takenaka, A., Igarashi, K., 1999: Protective effects of dietary Nasunin on paraquat induced oxidative stress. *Biosci. Biotechnol. Biochem.*, 63, 799–804.
9. Klaus, A., Herbert, H., 2004: Reactive oxygen species: Metabolism, oxidative stress and signal transduction. *Ann. Rev. Pl. Biol.*, 55, 373–399.
10. Klotzl, O., 2002: Oxidant-induced signaling: effects of peroxynitrite and singlet oxygen. *Biol. Chem.*, 383, 443–456.
11. Meng, Z., Bai, W., 2004: Oxidative damage of sulphur dioxide on testicles of mice. *Environ. Res.*, 96, 298–304.
12. Ohkawa, H., Ohishi, N., Yagi, Y., 1997: Assay of lipid peroxide by thiobarbituric acid reaction. *Anal. Biochem.*, 95, 351–358.
13. Patra, R., Swarp, D., Dwivedi, S., 2001: Antioxidant effects of tocopherol, ascorbic acid and L-methionine on lead-induced oxidative stress to the liver, kidney and brain in rats. *Toxicol.*, 162, 81–88.
14. Paglia, D.E., Valentine, W.N., 1967: Studies on the quantitative and characterization of erythrocyte glutathione peroxidase. *J. Lab. Clin. Med.*, 70, 158.
15. Ramanathan, K., Balakumar, B., Panneerselvam, C., 2002: Effects of ascorbic acid and alpha tocopherol on arsenic-induced oxidative stress. *Hum. Exp. Toxicol.*, 21, 675–680.
16. Sarmistha, S.R., 2000: The role of superoxide dismutase in combating oxidative stress in higher plants. *Bot. Rev.*, 66, 89–98.
17. Suntrass, Z.E., 2002: Role of antioxidants in paraquat toxicity. *Toxicol.*, 180, 65–77.
18. Tandon, S., Singh, S., Prasad, S., 2003: Reversal of cadmium induced oxidative stress by chelating agent, antioxidant or their combination in rat. *Toxicol. Lett.*, 145, 211–217.
19. Wang, C., Zhang, Y., Liang, J., 2006: Impacts of ascorbic acid and thiamine supplementation at different concentrations on lead toxicity in testis. *Clin. Chim Acta.*, 370, 82–88.
20. Wang, C., Liang, J., Zhang, C., Bi, Y., Shi, X., Shi, Q., 2007: Effects of ascorbic acid and thiamine supplementation at different concentrations on lead toxicity in liver. *Amer. Occup. Hyg.*, 51, 563–569.
21. Zhou, Y., Peng, Y., Deng, Z., 2003: Survey on outbreak of vitamin B₁ deficiency. *Journal of Chenzhou Medical College*, 5, 22–23.

Received February 24, 2011



STATISTICAL EVALUATION OF IMAGES PRODUCED BY X-RAY EXAMINATION OF DOGS FROM EASTERN SLOVAKIA BETWEEN 1999 AND 2008

Ševčík, A., Grunermelová, L., Ledecký, V.
Capík, I., Hluchý, M., Karasová, M.

Clinic for Small Animals, University of Veterinary Medicine and Pharmacy
Komenského 73, 04181 Košice
The Slovak Republic

sevcika@uvm.sk

ABSTRACT

This study presents the statistical evaluation of 8615 images obtained by X-ray examinations of dogs from Eastern Slovakia. Presented is the number of individual images according to respective anatomical structures and the frequency of examined breeds. This statistical evaluation of images obtained between 1999 and 2008, indicates the trend of development of this specific examination with a constantly increasing tendency.

Key words: anatomical structures; dog breeds; statistical evaluation of images; X-ray examination

INTRODUCTION

Wilhelm Conrad Röntgen, the discoverer of Röntgen rays or X-rays, pointed to the possibility of their use in medicine at the time of their discovery 115 years ago. Recently there has been rapid developments in radiology, regarding both the quality of the radiograms produced and the safety and mobility of X-ray machines. Today, the X-ray examination constitutes an essential diagnostic tool in veterinary medicine on almost a daily basis. This examination allows one to reject or confirm many presumed clinical diagnosis. It is used most frequently in dogs to diagnose: disorders of the locomotive apparatus; to detect some tumours as a part of cardiological and respiratory examination; disorders of the gastrointestinal and urogenital systems; stages of pregnancy

to determine number and positioning of foetuses with regard to potential complications at parturition; and for official evaluation of hereditary problems referred to as canine hip dysplasia (CHD) and canine elbow dysplasia (CED). The latter conditions are currently part of a compulsory monitoring system by breeder clubs in breeds predisposed to these diseases in order to increase the quality and overall level of dog breeding (6). Despite that, the majority of breeders focus on exterior properties of dogs and neglect some of the characteristics essentially important for the life of dogs. Radiology provides a range of imaging methods based on ionizing radiation skiagraphy which is the basis of more sophisticated methods, such as UltraSonoGraphy (USG), Computer Tomography (CT) and Magnetic Resonance Imaging (MRI) which, with the exception of ultrasonography, are used in veterinary medicine mostly in the western countries. However, we hope that in the near future these examination methods will be used also in our country.

The aim of our study was to evaluate statistically the images obtained by X-ray examination of dogs at the Clinic for Small Animals of the University of Veterinary Medicine and Pharmacy (UVMP) in Košice (previously Department of Surgery, Orthopaedics and Roentgenology) between 1999 and 2008.

METHODS

The X-ray examinations were carried out on the machine GIERTH HF-200, portable instrument CHIRAX 70 and the lamp DUROLUX CHIRANA. The machine was operated at an output




Fig. 1. Total number of X-ray examinations of dogs between 1999 and 2008

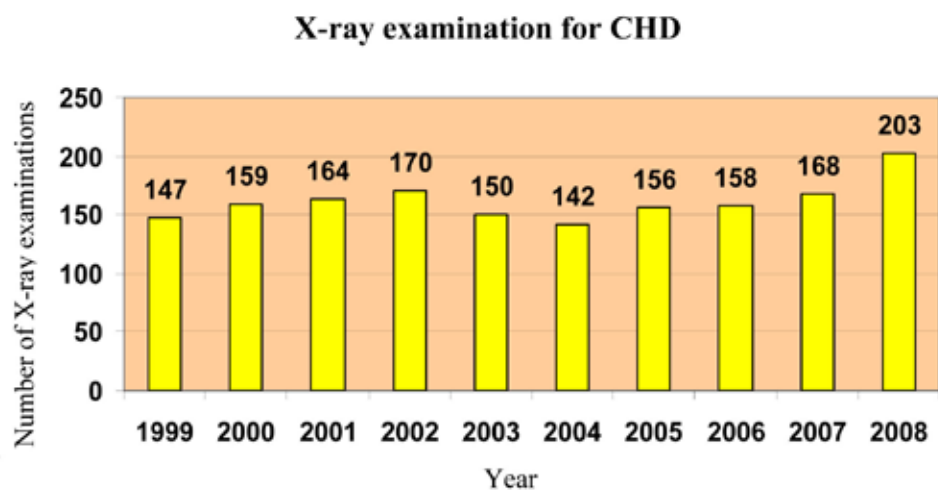


Fig. 2. X-ray examination for CHD

**The breeds most frequently examined for CHD
in 2008**

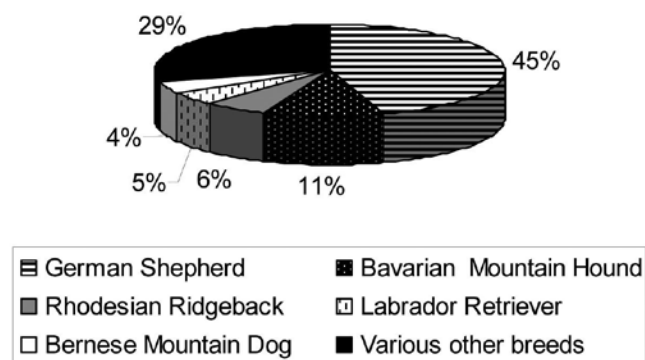


Fig. 3. The breeds most frequently examined for CHD in 2008

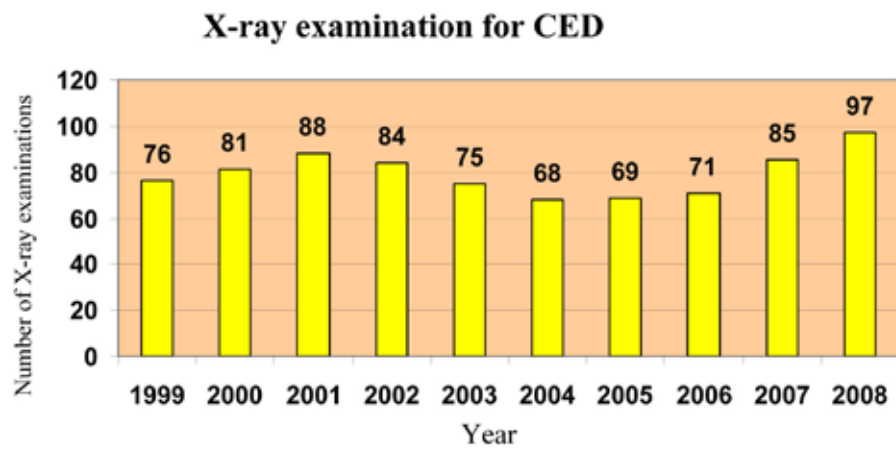


Fig. 4. X-ray examination for CED

The breeds frequently examined for CED in 2008

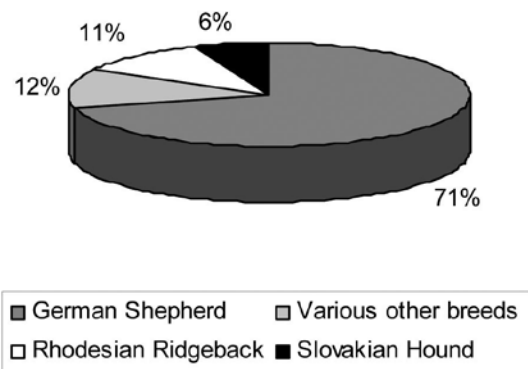


Fig. 5. The breeds most frequently examined for CED in 2008

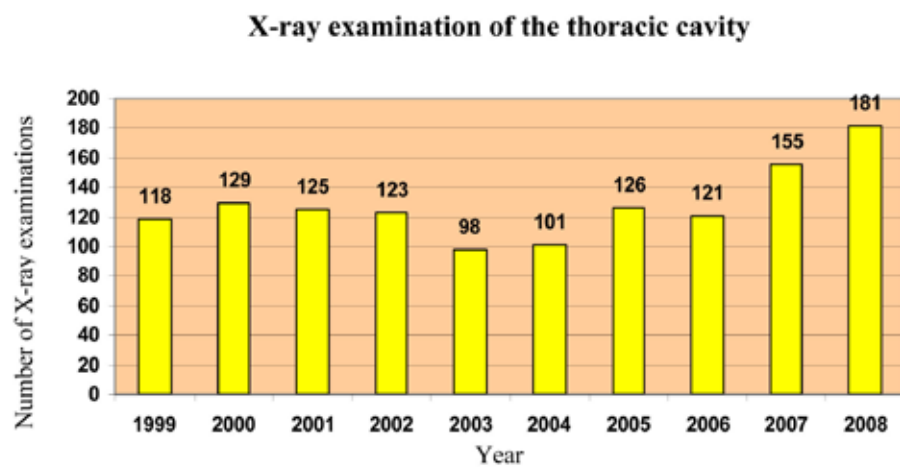


Fig. 6. X-ray examination of the thoracic cavity

The breeds most frequently subjected to X-ray examination of the thoracic cavity in 2008

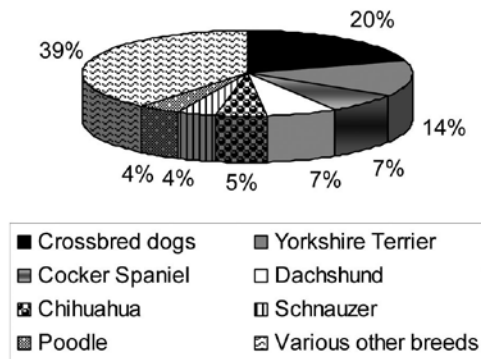


Fig. 7. The breeds most frequently subjected to X-ray examination of the thoracic cavity in 2008

X-ray examination of the abdominal cavity

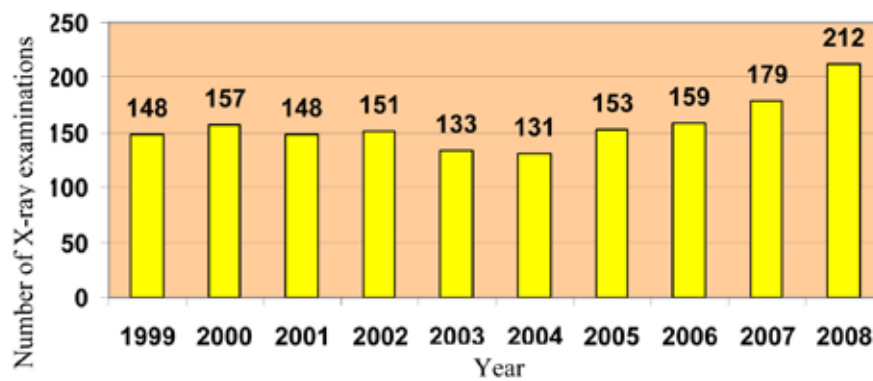


Fig. 8. X-ray examination of the abdominal cavity

The breeds most frequently subjected to X-ray examination of the abdominal cavity in 2008

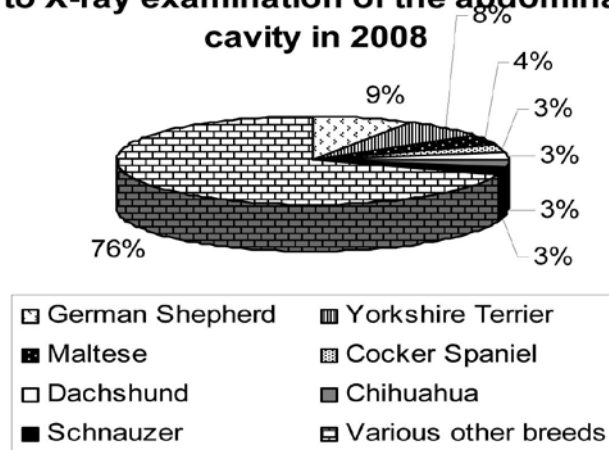


Fig. 9. The breeds most frequently subjected to X-ray examination of the abdominal cavity in 2008

X-ray examinations of the spinal column

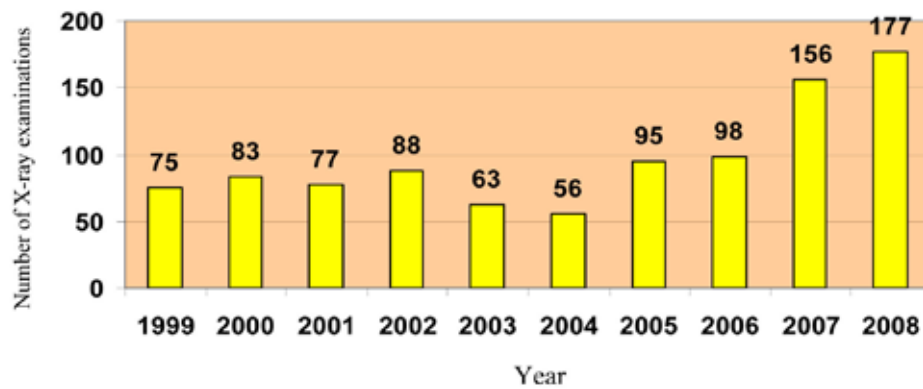


Fig. 10. X-ray examinations of the spinal column

The breeds most frequently subjected to X-ray examination of the spinal column in 2008

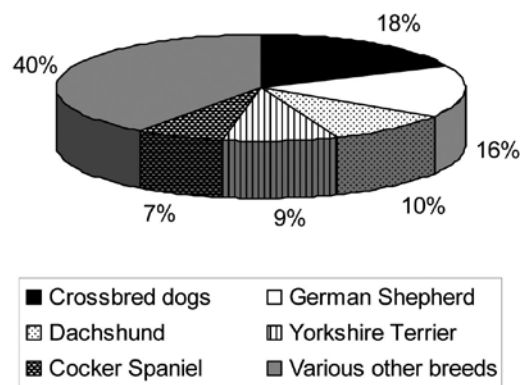


Fig. 11. The breeds most frequently subjected to X-ray examination of the spinal column in 2008

Number of X-ray examinations of the skull

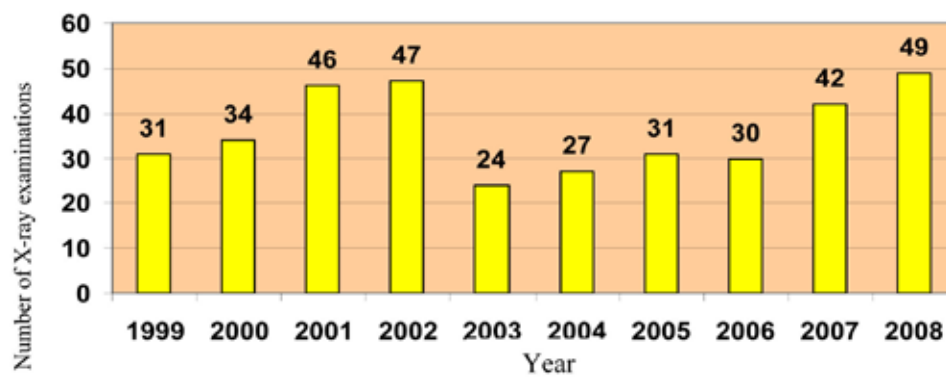


Fig. 12. Number of X-ray examinations of the skull

X-ray examination of thoracic and pelvic limbs

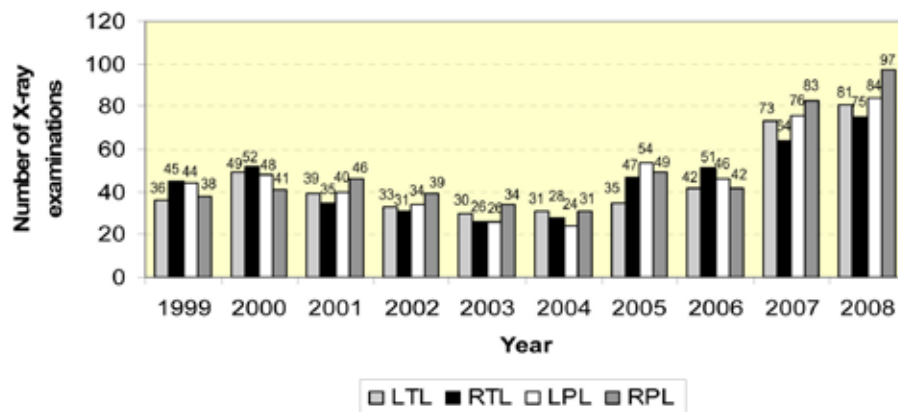


Fig. 13. X-ray examination of thoracic and pelvic limbs

X-ray examination of the pelvis

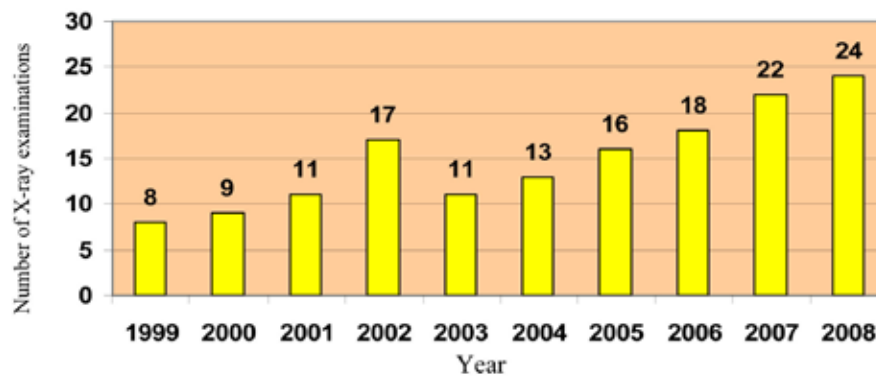


Fig. 14. X-ray examination of the pelvis

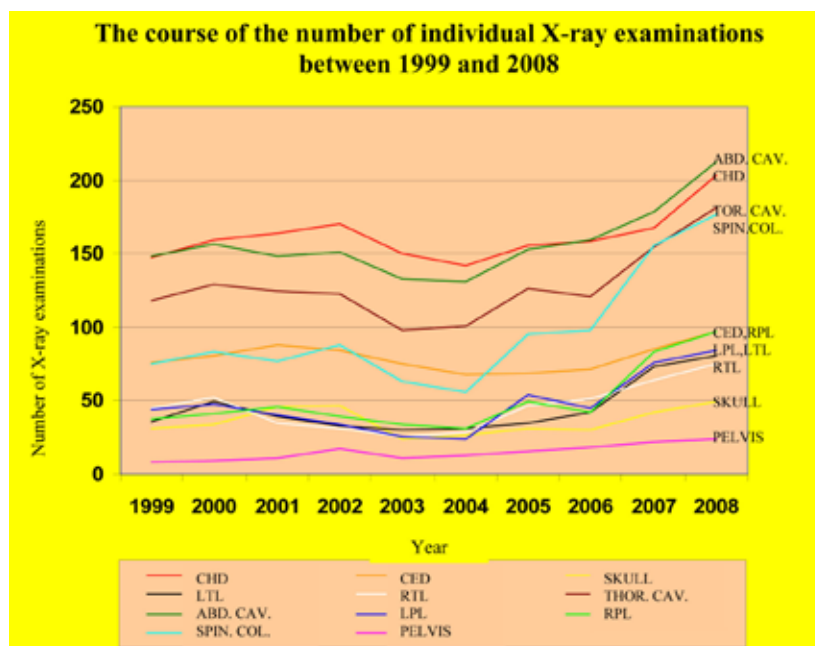


Fig. 15. The course of the number of individual X-ray examinations between 1999 and 2008

of 30–100 kV and 0.30–50 mAs in an effort to adjust to individual needs of the animals. The focal distance range was 70–100 cm. The radiographs were obtained under standard conditions at the Clinic for Small Animals, surgery section. X-ray films of dimensions 18×24 cm, 24×30 cm and 30×40 cm were used according to the size of the X-rayed body parts. The X-ray examination of the body parts wider than 10 cm was carried out by raster secondary aperture. During the examination the dogs were fixed, sedated or anaesthetized according to their health status and temperament and the projection demands. Radiographs were developed in a developing automat or in a wet way in a dark room.

Statistical evaluation of X-ray images

Between 1999 and 2008, the Clinic for Small Animals (previously the Department of Surgery, Orthopaedics and Roentgenology) carried out X-ray examinations of 8 615 dog patients from Eastern Slovakia. This does not include the number of projections and repeated examinations. We carried out a statistical evaluation and prepared: tables; comparative bar graphs; and pie charts with numerical and percentage expressions. The individual graph bars show the number of dogs examined in the respective years presented. Pie charts depict the most frequently examined breeds with respect to concrete anatomical body parts (thoracic cavity, abdominal cavity, limbs, spinal column). Diseases of the hip and elbow joints, CHD and CED, are very frequent diseases of dogs. Because of that, we constructed separate graphs showing its total incidence in dogs and breed diversification.

RESULTS

The statistics of the radiographic examinations of dogs between 1999 and 2008, carried out at the Clinic for small animals, UVMP in Košice.

Fig. 1 shows the total number of X-ray examinations of dogs over a ten year period. It is evident that the number of examinations showed an increasing trend after 2006 which indicates that X-ray examinations are presently an important examination method essential to obtain a correct diagnosis.

Fig. 2 shows the increase in the number of dogs examined for CHD starting from 2004. CHD is currently the most serious worldwide problem of dog breeding.

The breed most frequently examined for CHD was German Shepherd (45%; 91 dogs), followed by various other breeds (29%; 59 dogs), Bavarian Mountain Hound (11%; 22 dogs), Rhodesian Ridgeback (6%; 13 dogs), Labrador Retriever (5%; 10 dogs), Bernese Mountain Dog (4%; 8 dogs). Of all dogs examined in 2008 the A grade scoring (no sign of hip dysplasia) was detected in 76.7% ($n = 156$) of the dogs, B grade (marginal) in 13.3% ($n = 27$), C grade (mild) in 7.3% ($n = 15$) and D grade (moderate) in 2.4% ($n = 5$). The E grade (severe) was not observed in any of the examined dogs.

The bar graph shown in Fig. 4 shows the examinations carried out between 1999 and 2008, with the lowest number of examined dogs in 2004. Starting from the following year, the number of examinations for CED increased in relation to compulsory monitoring of this disease required by some breeding clubs in Slovakia.

The most frequently examined dog breed for CED shows the predominance of German Shepherd (71%; 69 dogs), similar to situation with CHD. The German Shepherd was followed by various other breeds (12%; 12 dogs), Rhodesian Ridgeback (11%; 10 dogs) and Slovakian Hound (6%; 6 dogs).

Fig. 6 shows no abrupt decrease or increase in the annual number of X-ray examinations of the thoracic cavity. There was a slight decrease in the years 2003 and 2004, the years of the lowest total number of X-rays of the thoracic cavity. The subsequent years brought an increase in such examinations which can indicate their role in diagnosis of diseases of the respiratory and cardiovascular systems.

Fig. 7 shows the proportion of dog breeds most frequently subjected to X-ray examination of the thoracic cavity in 2008. "Various other breeds" (39%; 71 dogs) was the most frequently examined, followed by crossbred dogs (20%; 36 dogs), Yorkshire Terriers (14%; 25 dogs), Cocker Spaniels (7%; 13 dogs), Dachshunds (7%; 13 dogs), Chihuahuas (5%; 9 dogs), Schnauzers (4%; 7 dogs) and Poodles (4%; 7 dogs).

Fig. 8 shows the number of X-ray examinations of the abdominal cavity. It showed the smallest variations in the number of examinations over the investigated 10-year period. It may be ascribed to the fact that diseases of the alimentary tract are common problems seen in everyday clinical practice.

The breeds most frequently subjected to X-ray examination of the abdominal cavity in 2008 were the predominant group composed from "various breeds" (67%; 142 dogs), German Shepherds (9%; 19 dogs), Yorkshire Terriers (8%; 17 dogs), Maltese dogs (4%; 9 dogs), Cocker Spaniels (3%; 7 dogs), Dachshunds (3%; 7 dogs), Chihuahua (3%; 7 dogs) and Schnauzers (3%; 7 dogs).

Fig. 10 shows the number of X-ray examinations of the spinal column and reveals the most abrupt increase in the number of examined patients starting from 2007. This may be a consequence of increasing occurrence of degenerative diseases (discopathies, spondylosis).

The breeds most frequently subjected to X-ray examination of the spinal column in 2008 were "various breeds" (40%; 71 dogs), crossbred dogs (18%; 32 dogs), German Shepherds (16%; 28 dogs), Dachshunds (10%; 18 dogs), Yorkshire Terriers (9%; 16 dogs) and Cocker Spaniels (7%; 12 dogs).

Fig. 12 shows variations in the number of X-ray examination of the skull. In the past two years their number increased to the level of years 2001 and 2002.

Fig. 13 shows the number of X-ray examinations of dog limbs in individual years. Totally, over the 10-year period, we examined 449 LTL (24%), 454 RTL (24%), 475 LPL (25%) and 500 RPL (27%). The above data indicate that the frequency of examination of all four limbs is approximately the same although the pelvic limbs are examined with somewhat higher frequency. We examined most frequently the right pelvic limb.

Fig. 14 shows the number of the least frequent X-ray examinations from among those that were subject of this investigation. However the annual number of X-ray examinations of the pelvis increases from year to year.

The line graph in Fig. 15 shows the course of the number of individual X-ray examinations over the 10 year period. Individual lines correspond to various examined anatomical structure. The frequency of X-ray examinations corresponded to the following descending sequence: CHD, abdominal cavity, thoracic cavity. The least frequently examined structure was the pelvis. Since 2006 the most abrupt increase has been for the examination of the spinal column.

The pie charts of dog breeds most frequently examined in 2008 pointed to the most numerous breed, the German Shepherd. The highest proportion of dogs of this breed was examined radiographically for anatomical structures CHD, CED, abdominal cavity and the spinal column.

DISCUSSION

The statistical evaluation of the results obtained between 1999 and 2008 indicated that the X-ray examination is an inseparable part of the diagnostic process and its importance is illustrated by its increasing utilization. This is witnessed by the 8615 dogs examined radiographically at the Clinic for Small Animals of UVMP in Košice. The reasons for the increasing trend in the number of dogs subjected to X-ray examination, most likely includes the increasing concern of the dog owners for their animals, socialisation of dogs, increasing expertness of veterinarians and their recognition of the diagnostic value of X-ray examinations. Last, but not least, is the value of the early detection of diseases, leading to the early elimination of the problems. The figures presented in this study indicated a poor utilization of this type of examination in the years 2003–2004. Several changes had occurred in Slovakia in these years: approval of new income tax act (flat income tax 19 %, minimisation of exceptions and taxation relief, increased consumption tax); new social security tax (reform of the continuous system of retirement assurance increase in retirement age to 62 years); increased consumption taxation (mineral oils, beer, tobacco and tobacco products); and obligation to use winter tires. Deficit of the state budget for 2004 reached 78.5 milliard Slovak crowns (10). Unemployment in the Košice region in 2003 reached 21.7 % which was the highest in Slovakia (7). Although no significant decrease in the economic growth was recorded in 2003–2004 and we could speak only about stagnation, the curve of macro-economic stability showed an abrupt decline down to negative values (8). All changes mentioned above might be related to the worsened economic situation of dog owners associated with decreased visiting to veterinary clinics and limited investments into the care of their household pets.

CHD is today one of the major problems of cynology on a worldwide scale and attracts most attention. It is the most widespread and best-known defect in dogs. For better illustration of the extent of the affliction of some breeds with CHD, we provide the following data: Germany 16 %, Switzerland 53 %, USA 70 % and Finland 53 %. The worldwide mean number of CHD affected dogs comes up to 30–40 % for most breeds, i.e. every third dog suffers from this problem (1).

Table 1. Frequency of occurrence of CHD according to breed (1)

1. St. Bernard Dog	11. Rottweiler
2. Newfoundland Dog	12. Gordon setter
3. Bullmastiff	13. Poodle
4. Bobtail	14. Giant Schnauzer
5. Spaniels	15. Rhodesian Ridgeback
6. English Setter	16. Weimaraner
7. Norwegian Elkhound	17. Irish Setter
8. Akita Inu	18. Keeshound
9. Golden Retriever	19. Great Dane
10. German Shepherd	20. Samoyed

Out of all the German Shepherds examined at the Clinic for Small Animals at the UVMP in 2008, 23.2 % of the dogs were affected with CHD compared to 76.8 % of the healthy dogs. Of all German Shepherds examined, the A grade of the scoring system (no sign of hip dysplasia) was ascribed to 76.8 % (n=156) dogs, B grade (marginal) affliction was detected in 13.3 % (n=27) dogs, C grade (mild) in 7.4 % (n=15), D grade (moderate) in 2.5 % (n=5) and E grade (severe) in 0 % of the examined dogs. The proportion of afflicted German Shepherds in Slovakia is lower than the worldwide mean, higher than that in Germany but considerably lower than in the other mentioned countries. The breed most frequently suffering from CHD in Slovakia is the German Shepherd, however, according to the statistics published on the website of the Orthopaedics Foundation for Animals (a worldwide accepted organisation established in 1966 with the aim to develop a programme for reduction of incidence of hereditary diseases) German Shepherd occupies only the 40th place in the list of 157 monitored breeds headed by Bulldogs (9). The results presented may be affected considerably by the popularity and number of dogs of the respective breeds in individual countries; by environmental factors; and last, but not least, the working load placed on the animals.

The examinations of the spinal column showed an increasing tendency in recent years. Compared to the situation in 2004, the number of these examinations increased more than 3-fold. They were most frequently used in German Shepherds (16 %). The occurrence of transient vertebra problems in the lumbosacral connection of the spinal column was described in large and heavy dog breeds, particularly in German Shepherds. The presence of transient vertebra problem produces: lumbalisation and sacralisation of the spinal column; asymmetric development of pelvis; degeneration of intervertebral disc; spondylosis; and symptoms of the cauda equina syndrome. In the majority of cases, the presence and development of the transitional segment is diagnosed accidentally at an early age, namely during preventive radiographic dia-

gnosis of CHD. The mean body weight of German Shepherd dogs increased over the past 30 years by 10–20 kilograms. Their thorax has lengthened and their limbs, particularly the thoracic limbs have shortened. These changes have not occurred with changes in the angles of the limb joints, their loading and development of bone and joint diseases (5). The second place on the list is occupied by the Dachshund with a 10 % incidence. The disease of the intervertebral disc is often seen in the chondrodystrophic dogs (Dachshund, Pekinese, Beagle). According to Lapallainen *et al.* (4), 16.5 % (13/79) of longhaired and 15.6 % (7/45) of wire-haired Dachshunds showed radiographic symptoms of intervertebral disc problems). The radiographic examination of the skulls showed no significant problems. The most frequent reason for the skull examination was to evaluate fractures, teeth, temporomandibular dislocations, bula tympany, paranasal cavities, neoplasms and foreign bodies (3).

CONCLUSION

The review of the most important data indicates the international character of X-ray diagnosis and techniques which by far have not reached the peak of their development. Success in radiographic diagnosis is not guaranteed solely by purchasing the latest instruments, but it requires: strict observation of rules of taking radiographs and their interpretation; complying with safety rules and continuous education; self correct adjustment of the X-ray machine; selection of suitable size and sensitivity of films; collimation of the primary bond; and appropriate fixation of the animals. If properly performed, X-rays allow the investigator to produce high quality X-ray images essential for evaluation and the making of correct diagnosis. Directional or hypothesis based viewing can be used to evaluate the radiograph. One should always observe the rule of viewing the entire X-ray image. Of the 8615 patients examined at our clinic we most frequently carried out X-ray examination for CHD. The breed most frequently examined in 2008 was the German Shepherd. It had the highest percentage in the examination for CHD, CED,

abdominal cavity and the spinal column. In the recent years, the highest increase was recorded in the examinations of the spinal column. Despite some sceptical views on the importance of radiography, the results of this study confirmed the justification of its use as a diagnostic method and its important role in present day modern veterinary medicine.

REFERENCES

1. Čoudek, K., 1998: Developmental diseases of limb skeleton (In Czech), www.cz-pes.cz.
2. Kealy, J.K., McAlister, H., 2000: *The Skull and Vertebral Column in Diagnostic Radiology and Ultrasonography of the Dog and Cat*. Saunders Company, 339–376.
3. Lappalainen, A., Norrgard, M., Alm, K., Snellman, M., Laitinen, O., 2001: Calcification of the intervertebral discs and curvature of the radius and ulna: A radiographic survey of Finnish miniature dachshunds. *Acta Vet. Scand.*, 42, 229–236.
4. Ledecký, V., 2006: Transient lumbosacral segment – lumbarization and sacralisation of the spinal column in dogs (In Slovak), www.rr.sk.
5. Ledecký, V., Ševčík, A., Capík, I., Mihály, M., 2006: Is it still necessary to use X-ray in veterinary practice? 110 years from the discovery of Röntgen radiation (In Slovak), *Infvet*, 1, 19–20.
6. Lednár, M., 2003: Unemployment in Slovakia (In Slovak). Statistical Office of the Slovak Republic, www.slovenska-republika.com.
7. Morvay, K., Okáli, I., 2007: Principal trends in the development of Slovak economy in 2006 and their assessment for 2007 (In Slovak), *Economical Journal*, 55, 539–553.
8. Orthopaedic Foundation for Animals, 2009: Hip dysplasia statistics, www.offa.com.
9. Zachar, D., 2004: *Reforms in Slovakia in 2003–2004, Evaluation of Economic and Social Measures* (In Slovak), Institute for economic and social reforms, SR, 148–152.

Received March 10, 2011



ACETYLCHOLINE AND CHOLINESTERASE IN RELATION TO PESTICIDES AND THEIR MORPHOGENETIC ROLES (A REVIEW)

Šťavová, L., Krešáková, L.

Department of Anatomy, Histology and Physiology, University of Veterinary Medicine and Pharmacy
Komenského 73, 041 81 Košice
The Slovak Republic

stavova@uvlf.sk

ABSTRACT

Xenobiotics are exogenous foreign substances having different effects on living organisms. One group of xenobiotics consists of agrochemicals, which includes pesticides that can be related to many health disorders. Agrochemicals used in agriculture, include a broad range of products. Some are used for the nutrition of plants or for the protection of fruits, while others involve the protection and nutrition of animals. Agrochemicals in the liver (through detoxification) can be transformed into reactive compounds with mutagenic, carcinogenic or teratogenic effects (the so-called biotransformations). Pesticides have significantly high biological activity and they are distributed worldwide. They have been exposed to large populations of living organisms in many different environments. The toxic effects of pesticides often are specific to certain species and they pose dangers to human health and both domestic and wild animals. The annual application of synthetic pesticides to food crops in the EU exceeds 140,000 tones, an amount that corresponds to 280 grammes per EU citizen per year. Many pesticides (mainly insecticides) are utilized, along with cholinesterase inhibitors, which have an intimate relationship to animal morphogenesis. Carbamate pesticides are cholinesterase inhibitors and can cause the reversible inhibition of acetylcholinesterase.

Key words: carbamates; cholinesterase inhibitors; morphogenesis; organophosphates; pesticides

MORPHOGENETIC ROLE OF ACETYLCHOLINE

The biological process of morphogenesis is a process in which living systems produce forms and structures through mechanical and biological factors including morphogens (19). Morphogens are developmental signals that exert specific effects on receptive cells, depending upon their concentration. They are present in gradients created by the presence of a “source” and a “sink”. Developing cells are affected in specific ways along this concentration gradient. However, it may also be appropriate to consider neurotransmitters as morphogens when they act as dose-dependent morphogenetic signals in neural and non-neural tissues. The stimulation of cholinergic receptors in target cells during a critical developmental period provides signals that influence cell replication and differentiation. Accordingly, environmental agents that promote cholinergic activity may evoke neurodevelopmental damage because of the inappropriate timing or the intensity of the stimulation (14).

Neurotransmitters participate in various forms of intra- and intercellular signaling throughout all stages of ontogenesis (5) and they exert their effects using receptors and signal transduction mechanisms similar to those in the adult nervous system (24). These substances and their specific receptors has been identified during the ontogeny of the mammalian nervous system, and it is now certain that transmitters play essential roles in the cellular and architectural development of the brain (30). During this period, receptor stimulation uniquely communicates with the genes that control cell differentiation, changing the ultimate fate of the cell.

The ontogenetic state of the target cell is critical in determining whether the outcome of the receptor stimulation has an effect on cell replication, differentiation, growth, death (apoptosis), or "learning"; that is, determining the future set-point for the responsiveness of the cell. At the same time, these multiple roles create a wide window of vulnerability in which exposure of the brain to neuroactive chemicals that elicit or block neurotransmitter responses can alter development. Thus, unlike classical teratology, (in which the first trimester of fetal development is the most sensitive target for the adverse effects of drugs or chemicals), certain agrochemicals may make the developing neurotransmitter system especially vulnerable to environmental neurotoxins, such as pesticides, which are designed to target receptors for these neurochemicals in lower organisms (24).

Acetylcholine (ACh) is synthesized from acetyl coenzyme A and choline by the enzyme choline acetyltransferase. In addition to its synthesis in the liver, choline employed in acetylcholine production is derived from dietary sources. There is a carrier system in the capillary endothelial cells that is responsible for the transport of choline, in its free and phospholipid forms, into the brain. ACh is a neurotransmitter widely diffused in central, peripheral, autonomic and enteric nervous systems. Presynaptic choline transport supports ACh production and release, and cholinergic terminals express a unique transporter critical for neurotransmitter release. Neurons cannot synthesize choline, which is ultimately derived from the diet and is delivered through the blood stream (1). ACh plays regulatory roles throughout ontogenesis, including the stages prior to the development of the nervous system (5). Acetylcholine is a major excitatory neurotransmitter in the nervous system of vertebrates and invertebrates. Accumulated evidence suggests that ACh also plays a key role: in the regulation of morphogenetic cell movements; cell proliferation; growth; and differentiation in species as diverse as echinoderms, insects, worms, avians, rodents, and humans (14). Evidence that ACh plays a key role in the neural development suggests that disruptions of cholinergic function could disturb these actions if present during key critical periods. The cerebral cortex may be especially vulnerable to such insults because of the important roles cholinergic afferents play in cerebral morphogenesis and synaptogenesis. Disruptions of cholinergic function that may have significant effects on brain development include alcohol, nicotine, and cholinergic pesticides (24).

In sea urchin embryos, cell movements occurring during gastrulation and postgastrulation stages appear to be regulated by ACh and biogenic monoamines (6). Similar functions of ACh during the gastrulation of vertebrate embryos are suggested by the presence of acetylcholinesterase (AChE) during gastrulation in the chick embryo (14).

MORPHOGENETIC ROLE OF CHOLINESTERASE

Developing animals are more sensitive than adults to acute cholinergic toxicity from anticholinesterases, including organophosphate and carbamate pesticides, when administered in a laboratory setting. It is also possible that these agents adversely affect the process of neural development itself, leading to permanent deficits in the architecture of the central and peripheral nervous systems. New evidence that AChE may have a direct role in neuronal differentia-

tion provides additional grounds for interest in the developmental toxicity of anticholinesterases. Still, developing rats recover faster from AChE inhibition than adults, larger due to the fact that developing organisms have a rapid synthesis of new AChE molecules. It therefore seems that either developmental toxicity may be unrelated to AChE inhibition, or that even a brief period of AChE inhibition is sufficient to disrupt development (25). Some selective cholinesterase inhibitors effectively suppress neurite outgrowth in model systems like differentiating neuroblastoma cells and explanted sensory ganglia. Certain of these "morphogenic" effects may depend on protein-protein interactions rather than catalytic AChE activity. It remains possible that some pesticides interfere with the important developmental functions of the cholinesterase enzyme family (4). Insecticides which enhance cholinergic effects through inhibition of cholinesterase are the most widespread chemical assaults on the fetus.

AChE is the enzyme that hydrolyzes the neurotransmitter acetylcholine at cholinergic synapses and neuromuscular junctions. The reaction that is catalysed by AChE is: $\text{ACh} + \text{H}_2\text{O} \rightarrow \text{choline} + \text{acetate}$. AChE is present in mammals, birds, fish, reptiles and insects (28). AChE predominates in neurons and muscle cells wherever cholinergic synapses are found. But the full picture is more complex, since AChE also occurs in non-neural and embryonic tissues like red blood cells, megakaryocytes, and migrating neural crest cells (4). The proposed noncholinergic roles for AChE range from neuromodulation by secreted forms, to promotion of cell proliferation in tumor growth and hematopoiesis (26).

Prenatal exposure to organophosphate and carbamate pesticides could have adverse effects on the neural development by interfering with the morphogenic function of AChE. The accumulating evidence indicates that AChE has extrasynaptic functions during neural development (3). This idea was initially based on *in vivo* observations that AChE is transiently expressed by neurons throughout periods of axonal outgrowth prior to synaptogenesis, a period during which the classical cholinolytic role for AChE in terminating nervous transmission is unnecessary. In the chick, transient AChE expression occurs in developing spinal cord neurons, which coincides with axonal outgrowth from these cells (29). In the peripheral nervous system, AChE is transiently expressed by developing dorsal root ganglion neurons and later in their axons and growth cones in the spinal cord. Together, these data strongly suggest that AChE plays a developmental role in the morphogenesis of the nervous system (3).

Although AChE may affect morphogenesis by noncatalytic mechanisms such as structural recognition, these actions could certainly be vulnerable to pesticides. However, the toxicologic data reviewed earlier indicate that those agents may have additional actions that would be deleterious to a growing nervous system. It seems wise to re-evaluate the developmental risks of anticholinesterases as data become available from ongoing studies of environmentally relevant molecules in neuronal culture and sensitive embryologic models of neural development (4).

Today we know of three isoforms of AChE:

- AChE-S (synaptic soluble) the major multimeric enzyme of brain and muscles;
- AChE-R ("read through") monomeric enzyme of embryonic and tumour cells;
- AChE-E (erythrocytes) associated with the erythrocyte membranes.

Prenatal development of the central cholinergic nervous system coupled with the important developmental roles played by ACh in both neural and non-neural tissues should make the vertebrate embryo especially vulnerable to the gestational effects of environmental neurotoxins that target cholinergic receptors or cholinesterase. It seems especially important to study the effects of chronic prenatal exposure to cholinergic pesticides on pre- and postnatal brain development as well as behavioral consequences of these exposures (14). Drugs or chemicals that target cholinergic neurotransmission probably represent the largest source of neurobehavioral teratogenesis. Agricultural and household pesticides that target AChE could interfere with the non-cholinergic role of AChE if exposure occurs during critical periods of nervous system development (3).

Given the widespread use and exposure to pesticides, the general lack of data on developmental neurotoxicity is a serious impediment. For certain pesticides, a requirement exists for neurotoxicity tests in adult animals, but developmental neurotoxicity is usually not considered when determining pesticide safety. Experimental, clinical, and epidemiologic evidence suggests that neurotoxic pesticides can also cause developmental neurotoxicity, and that the effects are more severe and lasting, and that they occur at much lower exposure levels. Given the likely environmental etiology of neurodevelopmental deficits and their importance to families and to society, prevention of exposures to neurotoxic pesticides should be made a public health priority (2).

CARBAMATES AND ORGANOPHOSPHATES AS INHIBITORS OF CHOLINESTERASE

Pesticides are a group of chemicals with high biological activity (20). Decades ago the activity of AChE was used as a sensitive indicator of exposure to organophosphate and carbamate pesticides. The inhibition of AChE is associated with a toxic mechanism of pesticide, with the pesticide's reversible or irreversible binding to the ester-point of the enzyme and with increasing of cholinergic effects on the nervous system (13). The inhibition of AChE by organophosphates takes place as a result of the phosphorylation of the serine residue in the active site of the enzyme. Carbamate pesticides are cholinesterase inhibitors with a similar mechanism of action as organophosphate pesticides. The hydroxyl of the serine residue within the active site of the enzyme is carbamylated instead of phosphorylated. Thus, AChE inhibition by carbamates lasts only minutes or hours, whereas the effects of organophosphates (OPs) with respect to AChE can last for 3–4 months (28). A number of pesticides belong to the group called cholinesterase inhibitors (ChEI), which affects morphogenesis. ChEI form a group of chemical compounds that prevent hydrolysis of acetylcholine (ACh; as a classical neurotransmitter of the autonomic nervous system providing communication between cells), thereby allowing the accumulation of ACh in the reactive sites of the living organism. Such activity may have some drugs (e.g. Alzheimer's disease and other dementia diseases called memory drugs) but also insecticides, respectively some chemical warfare agents that can be fatal for humans and animals (12).

Due to the fact that AChE is inhibited, ACh is not hydrolyzed and its accumulation occurs on the receptors of target cells. The accumulation effects are manifested by excessive stimulation of cho-

linergic synapses in the central and peripheral nervous system (8, 23). The most common accompanying symptom is the decrease of AChE activity in the blood and dysregulation of ions between the external and internal environment causing failure of the formation of action potentials in nerve endings (11, 17).

Changes induced by the action of ChEI can be divided into two effects:

1. muscarinic effect, and
2. nicotinic effect.

Both have central and peripheral effects.

Peripheral nicotinic effects cause fasciculation, muscle contraction, muscle pain, general weakness, tachycardia, hypertension, hyperglycaemia and mydriasis.

Peripheral muscarinic effects cause contraction of smooth muscles, stimulation of the glands, increased salivation, lacrimation, rhinorrhoea, bronchial secretion (bronchorexia), bronchial constriction, cyanosis, nausea, vomiting, incontinence (incontinentio urinae), bradycardia and pulmonary oedema.

Central effects cause insomnia, sleep disorders, headaches, dizziness, behavioral disorders, tremor, ataxia, respiratory depression, convulsions and coma (15).

ORGANOPHOSPHATES

OPs belong to a group of insecticides, which were discovered in 1938 by German chemists. OPs were used as nerve poisons during the World War II. At present, the OPs are used in agriculture and also used as antiparasitic substances for destroying insects such as fleas, lice and mosquitoes.

OPs replaced the forbidden organic chlorine compounds which were a major cause of poisoning in animals. They vary in toxicity, the level of residue and excretion. Many OP were developed to protect plants and animals and generally have an advantage by creating little or no residues in the tissues or in the environment. But it seems that chlorinated OP compounds have greater potential for producing tissue residues. Many OPs used as pesticides are not strong inhibitors of esterases, until they are activated by microsomal enzymes in the liver (27).

In severe cases of OP poisoning in adults (AChE inhibition exceeding 70%), a "cholinergic syndrome" is elicited, including various central nervous system effects such as headache, drowsiness, dizziness, confusion, blurred vision, slurred speech, ataxia, coma, convulsions and blockage of the respiratory centre. Some OPs can also induce a delayed neuropathy which does not involve inhibition of AChE but rather the neuropathy target esterase (NTE). The physiological functions of NTE are still unknown, and it is obscure how phosphorylation and aging of NTE leads to axonal degeneration. The syndromes described above are observed only following high doses with acute exposures to OPs. Survivors recover from these syndromes, but it is likely that the exposure also produces long-term adverse health effects. In rats, a single high exposure to an OP can cause long lasting behavioural effects and the same has been reported in several human studies (2). WHO estimates that each year there are 3 million cases of acute pesticide poisoning, and causes 220 000 deaths (9).

CARBAMATES

Carbamates are substances that were originally extracted from the bean called calabar, which is a native plant of West Africa. The extract obtained contained esters of physostigmine and methylcarbamate. Carbamates are considered a derivative of carbamic acid. Carbamates act as acetyl cholinesterase (AChE) inhibitors that affect lots of organs such as peripheral and central nervous systems, muscles, liver, pancreas and brain. Carbamate pesticides generally possess low toxicity for warm-blooded vertebrates, but developmental data are scarce (21). There are several reports about metabolic disorders, hyperglycemia, and also oxidative stress in acute and chronic exposures to pesticides that are linked with diabetes and other metabolic disorders. The induction of oxidative stress by some carbamates might also cause developmental neurotoxicity. In this respect, there are several *in vitro* and *in vivo* studies, but few clinical studies about the mechanism underlying these effects (10). When comparing the clinical course of carbamate poisoning (by aldicarb or methomyl) in young children (1–8 years old) and adults (17–41 years old), it was found that in children the predominant symptoms were CNS depression and hypotonia, and the most common muscarinic effect was diarrhoea. In adults the main symptoms were miosis and fasciculations, whereas CNS depression, hypotonia and diarrhoea were uncommon. An acute oral toxicity (LD50) was investigated in different adult mammals: rat, guinea pig, rabbit, and also in non-mammalian species: mallards duck, bobwhite quail, hen, fish and bees (22). As for the OPs, it is likely that poisoning with carbamates may result in long term neurological effects. Two patients showed cognitive deficit in attention, memory, perceptual and motor domains 12 months after a poisoning incident. With respect to the long term low level exposures to carbamates, reports concerning chronic toxicity are almost non-existent (2). The results indicated that carbamates impair the enzymatic pathways involved in the metabolism of carbohydrates, fats and protein within cytoplasm, mitochondria and peroxisomes (10). Also, carbamate insecticides inhibit cellular metabolism including energy, protein and nucleic acid metabolism, thereby, causing cell regression and death (18).

Carbamates represent besides AChE inhibitors also inhibitors of brain esterase (NTE neuropathy target esterase) leading to polyneuropathy. This neuropathy arises due to the degeneration of long axons of nerve cells. Brain NTE is a protein that is present in neurons as well as in other vertebrate cells and plays a role in the interaction between neurons and glial cells relevant in the evolving nervous system (7). Recent studies suggest that carbamates cause virtually 100% inhibition of NTE and polyneuropathy in chicken models (16).

No epidemiological studies of developmental neurotoxicity of carbamates in humans could be found in the literature, and the data from animal experiments are very sparse as well. Assuming that some of the neurotoxic effects observed in association with prenatal exposure to OPs, such as chlorpyrifos, are due to the inhibition of AChE, it is possible that carbamates may have similar developmental effects, even though the inhibition of AChE by carbamates is only transient (2).

REFERENCES

1. Amenta, F., Tayebati, S. K., 2008: Pathways of acetylcholine synthesis, transport and release as targets for treatment of adult-onset cognitive dysfunction. *Curr. Med. Chem.*, 15, 488–489.
2. Björling-Poulsen, M., Andersen, H. R., Grandjean, P., 2008: Potential developmental neurotoxicity of pesticides used in Europe. *Environ. Health*, 7, 1–22.
3. Bigbee, J. W., Sharma, K. V., Gupta, J. J., Dupree, J. L., 1999: Morphogenic role for acetylcholinesterase in axonal outgrowth during neural development. *Environ. Health Perspect.*, 107, Suppl. 1, 81–87.
4. Brimijoin, S., Koenigsberger, C., 1999: Cholinesterases in neural development: New findings and toxicologic implications. *Environ. Health Perspect.*, 107, Suppl. 1, 59–64.
5. Buznikov, G. A., Shmukler, Y. B., Lauder, J. M., 1996: From oocyte to neuron: do neurotransmitters function in the same way throughout development? *Cell. Mol. Neurobiol.*, 16, 537–539.
6. Falugi, C., 1993: Localization and possible role of molecules associated with the cholinergic system during “non-nervous” developmental events. *Eur. J. Histochem.*, 37, 287–294.
7. Glynn, P., 1999: Neuropathy target esterase. *Biochem. J.*, 344, 625–631.
8. Huff, F. J., Reiter, C. T., Rand, J. B., 1989: The ratio of acetylcholinesterase to butyrylcholinesterase influences the specificity of assays for each enzyme in human brain. *J. Neural. Transm.*, 75, 129–134.
9. Jaga, K., Dharmani, Ch., 2003: Sources of exposure to and public health implications of organophosphate pesticides. *Rev. Panam. Salud. Publica*, 14, 171–185.
10. Karami-Mohajeri, S., Abdollahi, M., 2010: Toxic effects of organophosphate, carbamate, and organochlorine pesticides on cellular metabolism of lipids, proteins, and carbohydrates: A comprehensive review. *Hum. Exp. Toxicol.*, Nov. 11 [Epub ahead of print].
11. Kassa, J., Samnaliev, I., 2004: Assessment of the therapeutic and anticonvulsive efficacy of a drug combination consisting of trihexyphenidyl and HI-6 in soman-poisoned rats. *Acta Medica (Hradec Kralove, CR)*, 47, 171–175.
12. Krall, W. J., Sramek, J. J., Catler, N. R., 1999: Cholinesterase inhibitors: a therapeutic strategy for Alzheimer disease. *Ann. Pharmacother.*, 33, 441–450.
13. Kristoff, G., Guerrero, N. V., Pechén de D’Angelo, A. M., Cochón, A. C., 2006: Inhibition of cholinesterase activity by azinphos-methyl in two freshwater invertebrates: *Biomphalaria glabrata* and *Lumbriculus variegatus*. *Toxicology*, 222, 185–194.
14. Lauder, J. M., Schambra, U. B., 1999: Morphogenetic roles of acetylcholine. *Environ. Health Perspect.*, 107, Suppl. 1, 65–69.
15. Leveridge, Y. R., 1998: Pesticide poisoning in Costa Rica during 1996. *Vet. Hum. Toxicol.*, 40, 42–44.
16. Lotti, M., Moretto, A. 2006: Do carbamates cause polyneuropathy? *Muscle Nerve*, 34, 499–502.
17. Mignini, F., Streccioni, V., Amenta, F., 2003: Autonomic innervation of immune organs and neuroimmune modulation. *Auton. Autacoid. Pharmacol.*, 23, 1–25.
18. Mohd. Amanullah, Hari, B. Y., 2011: Evaluation of carbamate insecticides as chemotherapeutic agents for cancer. *Indian J. Cancer*, 48, 74–79.

19. Petrovová, E., Lešník, F., Luptáková, L., Flešárová, S., Bálent, P., Valenčáková, A., 2007: Some aspects of morphogenesis (a review). *Folia Veterinaria*, 51, 197–201.
20. Petrovová, E., Luptáková, L., Maženský, D., Vdoviaková, K., 2010a: Bendiocarb embryotoxicity on the chick development from stage 20. *Folia Veterinaria*, 54, 46–50.
21. Petrovová, E., Maženský, D., Luptáková, L., Holovská, K., Špaleková, E., Massányi, P., Haladová, E., Tóth, T., 2010b: Alterations in the rabbit lymphoid tissue after bendiocarb administration. *J. Environ. Sci. Health. B*, 45, 719–728.
22. Petrovová, E., Maženský, D., Vdoviaková, K., Massányi, P., Luptáková, L., Smrčo, P., 2010c: Effect of bendiocarb development of the chick embryo. *J. Appl. Toxicol.*, 30, 397–401.
23. Ratner, D., Oren, B., Vidger, K., 1983: Chronic dietary anticholinesterase poisoning. *Isr. J. Med. Sci.*, 19, 810–814.
24. Slotkin, T.A., 1999: Developmental cholinotoxicants: nicotine and chlorpyrifos. *Environ. Health Perspect.*, 107, Suppl. 1, 71–80.
25. Slotkin, T.A., 2004: Cholinergic system in brain development and disruption by neurotoxicants: nicotine, environmental tobacco smoke, organophosphates. *Toxicol. Appl. Pharmacol.*, 198, 132–151.
26. Soreq, H., Patinkin, D., Lev-Lehman, E., Grifman, M., Ginzberg, D., Eckstein, F., Zakut, H., 1994: Antisense oligonucleotide inhibition of acetylcholinesterase gene expression induces progenitor cell expansion and suppresses hematopoietic apoptosis *ex vivo*. *Proc. Natl. Acad. Sci. USA*, 91, 7907–7911.
27. Toxicology, 1998: In *The Merck Veterinary Manual*, 8th edn., Aiello, S.E. (Ed.), 2015–2161, Merck and Co., Inc., Whitehouse Station, N.J., USA.
28. Van Dyk, J.S., Pletschke, B., 2011: Review on the use of enzymes for the detection of organochlorine, organophosphate and carbamate pesticides in the environment. *Chemosphere*, 82, 291–307.
29. Weikert, T., Rathjen, F.G., Layer, P.G., 1990: Developmental maps of acetylcholinesterase and G4-antigen of the early chicken brain: long distance tracts originate from AChE-producing cell bodies. *J. Neurobiol.*, 21, 482–498.
30. Whitaker-Azmitia, P.M., 1991: Role of serotonin and other neurotransmitter receptors in brain development: basis for developmental pharmacology. *Pharmacol. Rev.*, 43, 553–561.

Received March 22, 2011

COMPARISON OF COMPLEMENT FIXATION TEST AND ELISA IN THE LABORATORY DIAGNOSIS OF TOXOPLASMOSIS

Luptáková, L.¹, Petrovová, E.², Šťavová, L.¹, Maženský, D.²

¹ Department of Biology and Genetics, ² Department of Anatomy, Histology and Physiology
University of Veterinary Medicine and Pharmacy, Komenského 73, 041 81 Košice
The Slovak Republic

luptakova@uvlf.sk

ABSTRACT

The enzyme-linked immunosorbent assay (ELISA) was compared with the complement fixation test (CFT) for the detection of immunoglobulin G antibodies (IgG) as well as the overall antibody levels against *Toxoplasma gondii* in dogs. The study analyzed 102 samples of sera from asymptomatic dogs. By the complement fixation test, anti-*Toxoplasma* antibodies were found in 75 (73.5%) and by ELISA in 51 (50%) of the samples tested. Samples positive only by CFT were 39 (38.2%), only by ELISA 14 (13.7%), positive in both tests 37 (36.3%) and negative in both tests 12 (11.8%). This study showed a good qualitative correlation between the two tests used. The high correlation coefficient between the two tests suggests that the CFT should be a part of the basic examination procedures in the laboratory diagnosis of toxoplasmosis. This test is more significantly associated with the course of the disease.

Key words: complement fixation test; dogs; ELISA; specific antibodies; *Toxoplasma gondii*

INTRODUCTION

Toxoplasmosis is one of the most common parasitic zoonoses in the world afflicting a broad range of both mammals and birds. The etiological agent is *Toxoplasma gondii* (*T. gondii*) whose definitive hosts are the representatives of the family Felidae, which are infected by oocysts from the environment, or by tachyzoites and bradyzoites from the intermediary hosts, such as all kinds of vertebrates, including humans. It is a pantropical cosmopolite and facultatively heterogenic coccidium (3).

The disease is mostly asymptomatic in animals; however, there are exceptions. Toxoplasmosis may affect a number of organs, but it primarily affects lungs, the central nervous system (CNS) and the eyes. In gravid animals, particularly in sheep and goats, the *T. gondii* infections causes embryonic mortality, foetal death or abortion, depending on the stage of gravidity in which the infection occurred (2). The variation in the clinical presentation and the severity of disease has been attributed to several factors, including the heterogeneity of the host and the genotype of the infective parasite (8).

Toxoplasmosis of pet animals, such as dogs, cats and rabbits, is also an important source of the infection. In dogs, toxoplasmosis is a rare primary disease. Martins and Viana (9) highlight the importance of dogs in the epidemiological chain of the disease, through the habit of ingesting, and rolling in, cat feces, thus permitting transmission of oocysts by contact of the contaminated hide. Lindsay *et al.* (7) demonstrated that after ingestion of *T. gondii* non-sporulated oocysts, these oocytes could pass through the intestinal tract of dogs, and be excreted in their infectious stage, re-enforcing the theory that dogs act as mechanical vectors of oocysts. The sources of the contamination by oocysts are mainly moist and shady places frequented by cats, where there are suitable conditions for the surviving of oocysts for a long period in the external environment (14).

Serological diagnosis of *T. gondii* infections in dogs has been evaluated by many investigators (11, 4, 15). The tests used include: the Sabin-Feldman; the complement fixation; the indirect haemagglutination; the direct agglutination; the indirect fluorescent antibody; and the enzyme immunoassay. The demonstration of antibodies by these serological tests just indicates previous infection by *T. gondii*. A laboratory diagnosis of an ongoing acute toxoplasmosis infection requires the demonstration of high titres of specific an-

tibodies and increasing levels in two serum samples taken 2 to 4 weeks apart (13).

The aim of our study was to compare the two serological tests for detection of *Toxoplasma gondii*-specific antibodies in dogs in the Slovak Republic.

MATERIAL AND METHODS

Animal sera

A total of 102 serum samples were obtained from asymptomatic dogs in Slovakia. The dogs were of various pure and mixed breed ancestries. The sera were collected following centrifugation at 2500 rpm of 2 ml of the blood samples obtained from the vena cephalica from the dogs and were stored at -20°C until analyzed for *Toxoplasma* antibodies.

Serological tests

The CFT was performed by the micromodified method of Zás-
tĕra *et al.* (16) published as a supplement to the standard method in Acta Hygienica, Epidemiologica et Microbiologica. The test is performed in two steps. The first step resides in the incubation of the mixture of the antigen and antibody together with complement (its optimum concentration is tested in advance). The second step consists of the detection of free or not fixed complement after its reaction with the immunity complex, while the suspension ready-to-use haemolytic system is used as an indicator. The activity of the complement is determined quantitatively as 50% hemolysis of the haemolytic system. The basic dilution was 1:8 and this titre was considered positive.

For the diagnosis of *Toxoplasma* antigen (Virion, Switzerland), complement (made from guinea pig serum, Virion, Switzerland; work dilution 1:47.5), *Toxoplasma* positive and negative serum (Imuna a.s., the Slovak Republic), and Hemolytic system (ready to use; Virion, Switzerland) were used.

An immunoenzymatic test (ELISA) was carried out for the detection of the anti-*T. gondii* IgG antibodies. The IgG antibodies were detected by a commercial kit of *Toxoplasma gondii* IgG (Test-Line, the Czech Republic). The reaction is based on the principle of indirect enzymatic reaction. In the first step, specific IgG antibodies present in serum will bind to the antigen of *T. gondii* coating the surface of the reagent wells. After replacement of the residue of the free antibodies, the rabbit anti-dog IgG labeled with peroxidase (Sigma-Aldrich, USA) was applied to the complex of antigen and antibody. After the addition of the TMB ELISA substrate (3,3',5,5'-tetramethylbenzidine), the absorbance was read at 450 nm using a Dynex spectrophotometer (Dynex Technologies, USA). Positive and negative serum controls, previously tested by conventional serological tests, were included on each plate. The limit cut-off titre was assessed for ELISA assessment uniformly at 1:100. Index of positivity was 1.0 and higher.

Statistical analysis

The positive and negative results obtained only in CFT, only in ELISA and in both tests were statistically analyzed by Chi-square test. The correlation coefficient was determined by comparing CFT titres and concentration of IgG antibodies obtained by ELISA.

RESULTS

In our study, we examined 102 dog serum specimens for the presence of antibodies to *T. gondii* by two serological tests (CFT and ELISA). The presence of antibodies to *T. gondii* was detected in 75 cases (73.5%). Anti-*Toxoplasma* IgG antibodies were found in 51 (50%) by ELISA. Samples positive only with CFT were 39 (38.2%), only in ELISA 14 (13.7%), positive in both tests 37 (36.3%) and negative in both tests 12 (11.8%) (Fig. 1). The qualitative correlation between CFT and ELISA IgG antibodies was reflected in a correlation coefficient $r=0.918$ (Table 1). The titres of latent infection (1:8–1:128) in CFT were recorded in 75 dogs: 13 dogs (12.7%; 1:8), 20 dogs (19.6%; 1:16), 20 dogs (19.6%; 1:32), 20 dogs (19.6%; 1:64) and 1 dog (1%; 1:128). The prevalence of acute infection (1:256 and higher) was recorded in 1 dog (1%; 1:256). The coincidence of CFT and IgG antibodies was recorded in 37 samples (36.3%) (Fig. 1). Comparison of the detection of antibodies by these two tests was statistically significant ($P<0.001$; Fig. 2).

Table 1. Coincidence of overall antibodies (CFT) and IgG antibodies (ELISA) in dependence on CFT titres ($r = 0.918$)

Titres	Positive CFT		Positive ELISA	
	n	%	n	%
1:8	13	12.7	6	5.9
1:16	20	19.6	8	7.8
1:32	20	19.6	12	11.8
1:64	20	19.6	11	10.8

DISCUSSION

The complement fixation test is the basic method in the diagnosis of toxoplasmosis. Despite its standard and reproducible results, it is rarely used in the routine diagnosis of toxoplasmosis where the detection of IgG by means of ELISA is widely used. Our results suggested that CFT is a reliable indicator of *Toxoplasma* infection as there was a correlation between CFT and IgG ELISA ($r=0.918$). In our study, 36.3% of the samples were positive in both tests and 38.2% of the examined samples were positive only in CFT. The significant differences in results obtained by CFT and ELISA could be influenced also by the higher positive titer established in ELISA (1:100). Also it is possible that this difference is due to the fact that by CFT we detected overall antibodies (characteristic for acute and chronic reaction) but by ELISA we detected only IgG antibodies (characteristic mainly for chronic infection) not overall antibodies.

Ondriská *et al.* (10) analyzed 1705 samples of serum from human patients by CFT and IgA, IgM and IgG ELISA. They found a dependence when comparing the CFT titres and

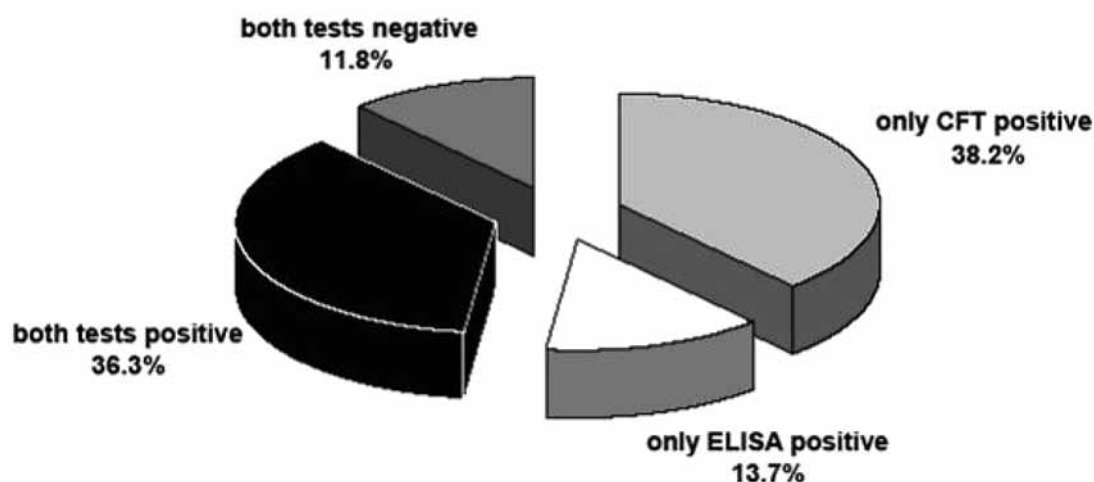


Fig. 1. Comparison of qualitative results for CFT and ELISA (n = 102)

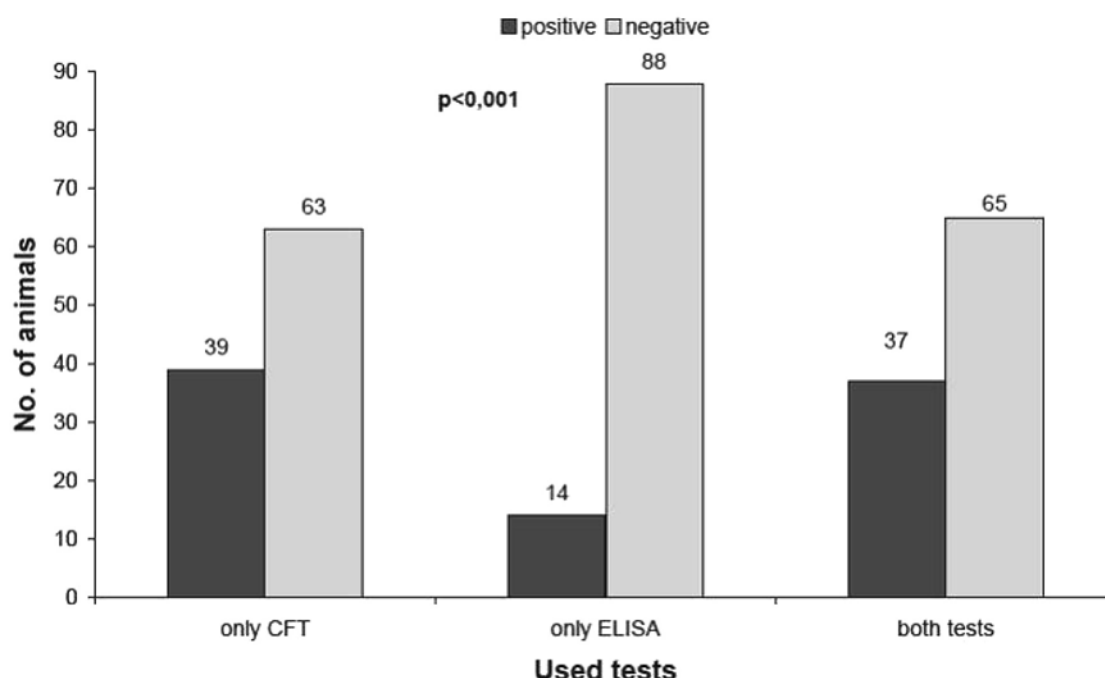


Fig. 2. Number of animals positive only in CFT, only in ELISA and in both tests ($P < 0.001$).
 P^* value was obtained by comparing results obtained by CFT to results obtained only by ELISA

the concentrations of IgG antibodies ($r = 0.549$; $P < 0.05$). A higher correlation was found when comparing the CFT titres and concentrations of IgA antibodies ($r = 0.956$).

The limiting criterion for the evaluation of laboratory results is the assessment of the limiting cut-off value for the substance being assessed in a reaction. In view of the individual immunoreactivity and reactivity implied from organ localization of infection, the determination of the CFT value is problematic and therefore it is more suitable to use the term of “diagnostically significant value”. For example, whi-

le Feldner (5) considers CFT titer equal to or over 1:10 in the correlation with positive IgM antibodies to be characteristic for acute infection, according to Čatár *et al.* (1) this titre is more frequent in latent infections. Flegr and Havlíček (6) considered the titres as high as 1:128 to be significant. According to these authors the titres equal to or below 1:64 are detected mostly in patients with chronic or latent infection. In our study we found mostly titres characteristic of latent infection and only one sample showed a titer (1:256) associated with acute infection.

CONCLUSIONS

The specific IgG antibodies detected by ELISA are a reliable substitution of quantitative results that can be assessed by CFT, but due to the fact that the dynamics of CFT antibodies are more significantly associated with the course of the disease, the assessment of the phase of the infection must be supported also by parallel examinations of IgM or IgA antibodies (12). So the CFT should be the first part of the basic examination procedures in the laboratory diagnosis of toxoplasmosis.

ACKNOWLEDGEMENTS

This paper is a result of research work done within the institutional grant of St. Elizabeth University of Health Care and Social Work, n. o., Bratislava and within the projects VEGA of the Ministry of Education of the Slovak Republic No. 1/0271/11 and 1/0108/10.

REFERENCES

1. Čatár, G., Hynie-Holková, R., Zachar, M., 1967: Comparison of indirect immunofluorescence test and complement binding reaction for toxoplasmosis (In Slovak). *Bratislavské Lekárske Listy* (Bratislava Medical Letters), 47, 219–225.
2. Davidson, M. G., 2000: Toxoplasmosis. *Veterinary Clinics of North America: Small Animal Practice.*, 30, 1051–62.
3. Dubey, J. P., Beattie, C. P., 1988: *Toxoplasmosis of animals and man*. Boca Raton, Florida, CRC Press, USA, 232.
4. Dubey, J. P., Stone, D., Kwok, O., Sharma, R., 2008: *Toxoplasma gondii* and *Neospora caninum* antibodies in dogs from Grenada, West Indies. *J. Parasitol.*, 94, 750–751.
5. Feldner, J., 1991: *Toxoplasmosis*. Behringwerke AG., 3, 1–39.
6. Flegr, J., Havlíček, J., 1999: Change in the personality profile of young women with latent toxoplasmosis. *Fol. Parasitol.*, 46, 22–28.
7. Lindsay, D. S., Dubey, J. P., Butler, J. M., Blagburn, B. L., 1997: Mechanical transmission of *Toxoplasma gondii* oocysts by dogs. *Vet. Parasitol.*, 73, 27–33.
8. Malčecová, B., Valenčáková, A., Kovács, K., Kalenichová, Z., Bálent, P., 2008: Genetic characteristics and geographic appearance genotypes of *Toxoplasma gondii*. Proceedings *Topical Issues of Animal Bioclimatology 2008*, December 9th, Brno, Czech Republic, 57–59.
9. Martins, C. S., Viana, J. A., 1988: Toxoplasmosis – O que todo profissional de saúde deve saber. *Revista Clínica Veterinária.*, 15, 33–37.
10. Ondriska, F., Čatár, G., Vozárov, G., 2003: The significance of complement fixation test in clinical diagnosis of toxoplasmosis. *Bratislavské Lekárske Listy* (Bratislava Medical Letters), 104, 189–96.
11. Sedlák, K., Bártová, E., 2006: The prevalence of *Toxoplasma gondii* IgM and IgG antibodies in dogs and cats from the Czech Republic. *Vet. Med.-Czech.*, 51, 555–558.
12. Sýkora, J., Poledňáková, S., 1993: Determination of IgG *toxoplasma* antibodies by ELISA with uniform dilution of sera (In Czech). *Československá Epidemiologie* (Czechoslovak Epidemiology), 44, 107–110.
13. Tenter, A. M., Heckeroth, A. R., Weiss, L. M., 2000: *Toxoplasma gondii*: from animals to humans. *International Journal for Parasitology*, 30, 1217–58.
14. Valenčáková, A., Malčecová, B., 2008: Detection of oocysts *Toxoplasma gondii* in environmental samples. Proceedings *Topical Issues of Animal Bioclimatology 2008*, December 9th, Brno, Czech Republic, 100–102.
15. Watson, A. D. J., Farrow, B. R. H., McDonald, P. J., 2008: Prevalence of *Toxoplasma gondii* antibodies in pet dogs and cats. *Aust. Vet. J.*, 58, 213–214.
16. Zástěra, M., Pokorný, J., Jíra, J., Valkoun, A., 1986: Supplement of standard methods of laboratory diagnostics of toxoplasmosis (in Czech). *Acta Hygienica Epidemiologica et Microbiologica*, 3, 3–14.

Received May 3, 2011

CHARACTERIZATION OF DIFFERENT PCR METHODS FOR THE IDENTIFICATION OF *CRYPTOSPORIDIUM* SPP.

Ravaszová, P., Valenčáková, A., Luptáková, L., Malčeková, B., Goldová, M.

University of Veterinary Medicine and Pharmacy, Komenského 73, 04181 Košice
The Slovak Republic

ravaszova@uvm.sk

ABSTRACT

Since *Cryptosporidium* is an important waterborne pathogen that infects the gastrointestinal and respiratory tracts of mammals, including humans, diagnosis of cryptosporidium infections is an important aspect of public health. A number of nucleic acid based methods have been utilized for the identification of the species and for the specific diagnoses of human and animal cryptosporidiosis. Some of these methods are used for the simultaneous identification of various species of *Cryptosporidium* in clinical samples (multiplex PCR, DNA microarray). Others are used to shorten the time of the assays (Real time PCR with HRM analysis, PCR-RFLP), or to make the assay more specific (nested PCR). Nevertheless, all of the above mentioned methods have their pros and cons. In this paper, we introduce some of the recently used methods in molecular biology.

Key words: *Cryptosporidium*; PCR; DNA

INTRODUCTION

Cryptosporidiosis, also known as crypto, is a parasitic disease caused by *Cryptosporidium*, a protozoan parasite in the phylum Apicomplexa. It affects the intestines of mammals and is typically an acute short-term infection. It is spread through the fecal-oral route, often through contaminated water; the main symptom is self-limiting diarrhea in people and animals with intact immune systems. However, in immunocompromised and immature individuals, the symptoms are particularly severe and often fatal. In Milwaukee in 2003, during an epidemic of cryptosporidiosis (the largest of its kind), 73 % of AIDS patients with CD4⁺ counts lower than 50 cells.

mm⁻³ and 36 % of those with counts between 50 and 200 cells.mm⁻³ died within the first year of contracting the infection (4). One of the largest challenges in identifying such outbreaks is the ability to identify *Cryptosporidium* in the laboratory. Real-time monitoring technology is now able to detect *Cryptosporidium* with online systems, unlike the spot and batch testing methods used in the past.

The most important zoonotic reservoirs are cattle, sheep and goats. Additionally, in recent years, cryptosporidiosis has plagued many commercial leopard gecko breeders. Several species of the *Cryptosporidium* family (*C. serpentis* and others) are involved, and besides geckos it has been found in monitor lizards, iguanas and tortoises, as well as several snake species.

Since the use of microscopic, immunologic and cytometric methods for the detection of *Cryptosporidium* oocysts is restricted, a number of nucleic acid based methods have been applied in the past few years. These methods are mainly used for: identification of species; for detection of genetic variations among the species in the fecal, environmental or water samples; as well as for; a specific diagnosis of human or animal cryptosporidiosis. Some of these methods rely on a specific in situ hybridization of probes, with specific gene loci in a cryptosporidial oocyst, but most of the methods rely on a specific amplification of one or more loci of a small amount of genomic DNA in the PCR reaction. Application of the methods of molecular biology lead to better understanding of systematics, biology, ecology and population genetics of *Cryptosporidium* species, which enables us to improve the strategies of prevention, surveillance and control of human and animal cryptosporidiosis.

Real Time PCR and HRM analysis

Real Time PCR is a laboratory method based on the PCR. This method allows simultaneous amplification and quantification of

target DNA molecules. The key feature of the method is a new approach to the detection of amplified DNA, which happens in real time during the amplification itself, compared to a standard PCR, in which the DNA product is detected at the end of a reaction during electrophoresis (17). The detection of the amplified product using a fluorescent probe during PCR cycling, eliminates post-PCR processing and produces results within 30 to 90 minutes, depending on the type of real-time instrumentation that is employed (6).

There are two methods used in the detection of the product in Real Time PCR. The first one involves a non-specific intercalate dye that binds to any dsDNA. The second one involves a sequence specific DNA probe composed of oligonucleotides that are labeled with a fluorescent reporter. The labelled fluorescent reporter, allows detection only after hybridization of the probe with a complementary DNA target.

Very often, for quantification of mRNA and non-coding RNA in cells or tissues, the real time PCR is combined with reverse transcription (5). It can be used for relative or absolute quantification of nucleic acids. In relative quantification, the common multiples of a target sequence are measured, meanwhile the absolute quantification gives us the exact number of the target molecules present in the reaction compared to a known standard. Therefore, the quality of the standard is very important for accurate quantification.

High resolution melt (HRM) analysis is a method for comparing melting curves in order to detect the sequence differences among the isolates. It analyses the basic behavior of nucleotides during the PCR. HRM analysis is used mainly for mutation scanning and single nucleotide polymorphism genotyping, as well as for pathogen typing. The assumption is that the next utilization of possibilities for the HRM analysis will be: multiplex SNP genotyping; gene scanning for mutation identification; methylation studies; phylogenetic detection; and many more surveys based on sequencing. The limitation of HRM analysis could be A/T SNP mutations, because of the possibility of identical melting profiles between different amplicons, which disables the samples to be distinguished only by means of HRM analysis, or the routine genotyping of known SNP mutations for small differences in melting temperatures between homozygous samples (9).

Pangasa *et al.* (9) used for the HRM analysis of faecal samples, ITS-2 domain. ITS-2 amplicons of 440–450 bp were bigger than those normally used for HRM analysis, which probably reduced the capacity for the mutation detection. But despite that fact, the specific identification and differentiation among the samples was achieved. Moreover, different studies proved that multipeak melting profiles are reproducible and have diagnostic significance, because they provide a unique profile with the increased number of characters for determination of the species and genotypes. For instance, Robinson *et al.* (11) used the melting-curve analysis to discriminate between seven species of *Naegleria* (Protista) and to differentiate them from the closely related *Williaertia magna*, using a single amplicon (330–400 bp), which represented ITS-1, 5.8S and ITS-2 of nuclear rDNA.

Several previous studies, which used PCR-RFLP analysis or specific PCR, described mixed infections of *C. hominis* and *C. parvum* in human, but they were not able to prove the presence of both species in amplicons of direct PCR sequencing. PCR coupled by HRM analysis of examined samples demonstrated (following SSCP analysis) the presence of *C. hominis*, *C. parvum* or *C. hominis* and

C. parvum DNA, and thus confirmed the capability of this approach to detect mixed infections (9). Despite that, based on unpublished findings, it can not be expected that the HRM analysis will be constantly achieving the sensitivity and accuracy of the SSCP method for the visual detection of both of the parasites *C. hominis* and *C. parvum* in the samples. This potential application limit of HRM analysis can be overcome by the parallel usage of multiplex-tandem PCR (13) or probe – PCR (10) with HRM analysis (9).

Nested PCR

Nested PCR is a modification of the PCR in order to reduce the contamination of products by amplification of unexpected primer binding sites. Nested PCR involves two sets of primers, that are used in two subsequent PCR reactions. The second primer pair amplifies the secondary target that is found among the products of the first PCR reaction. This strategy minimizes the possibility of amplification of a wrong locus in the second PCR, even though it can occur during the first PCR reaction. Also, the use of two primer sets enhances the specificity of the PCR reaction, because creation of the final product depends on the binding of two different primer sets, which should reduce the need to use additional confirmatory methods, which would be blotting, restriction digestion or sequencing. There are several primer pairs that are frequently used in the diagnosis of cryptosporidiosis. The group involves primers Sula. HSP70 1st/2ndF/R (16), Xiao-rRNA-1st/2ndPCR-F/R (20), NDI-AGF2/R2 and CPB DIAGF/R (8).

PCR-RFLP

The PCR-RFLP method (Restriction Fragment Length Polymorphism) – uses restriction endonucleases for the cleavage of the polynucleotide chain in the specific sites. The method enables the detection of mutations in a relatively short DNA section which is a product of the previous PCR reaction. The advantage of this method is its simplicity, but the probability of the mutation detection is relatively low, since it depends on the number of enzymes used in the reaction. Restriction enzymes are used to differentiate various *Cryptosporidium* spp. depending on the number and size of the bands. Differentiation of *Cryptosporidium* spp. is based on 830 bp fragment of SSU rRNA gene. The restriction enzymes frequently used in the reactions are SspI, VspI (20), DraI, but there are some other restriction enzymes, that can be used, for instance TaqI, AseI, MseI, BstUI, SimI, FmuI (2).

Fingerprinting

This method involves the screening for sequence variations and organizations in the genome. The advantage could be that for the characterization of a parasite, no previous information on the genome sequence is needed. A disadvantage is that the genetic fingerprint of the organisms in the sample represents more a population of organisms than a single individual.

PCR with arbitrary primers (AP-PCR, (19)) and randomly amplified polymorphic DNA (RAPD-PCR, (14)) are based on the amplification of DNA fragments from genomic DNA using individual arbitrary sequence oligoprimers (10-mer) and on subsequent separation of amplicons on agarose or polyacrylamide gel electrophoresis. The size of the amplified primers differs among the species. Closely related taxa have a very similar distribution of fragments, while poorly related taxa have greater distances between their fragments (18).

However, fingerprinting methods have their disadvantages, which is their inability to reproduce the same results. Even small differences between the annealing temperatures can affect the process of band creation. Factors that influenced the annealing temperatures were well documented and they involved: a thermocycler model and program; components in the reaction mixture; DNA concentration and purity; type, source and concentration of thermostable polymerase; and further buffer conditions. While many of these factors can be checked by using the precise terminology, the fine anomalies in the components of the reaction mixtures, such as the variations in the thermocycler temperature profiles are sometimes hard to monitor.

Multiplex PCR

This PCR method is used for the simultaneous identification of various species of *Cryptosporidium* in clinical samples. It is the alternative to the PCR followed by RFLP or gene sequencing, which are, in fact, time and money consuming and therefore their usage is limited because of the higher cost to some laboratories of public health. Multiplex PCR was used for the simultaneous detection of four types of cryptosporidial oocysts present in cattle feces. This method of mixed infection detection was described, with its reduction of time and money needed for the examination of the samples, when compared with conventional sequencing methods. Also, the limitations of sequencing, as the final method for detection in mixed samples, were described (12). Multiplex PCR is often combined with nested PCR; while it is common to use degenerated primers which are able to amplify a fragment of an actin gene from a clinical sample, where one may expect mixed infections. Santin and Zarlenga (12) described that the sensitivity of multiplex PCR is not sufficient for the detection of DNA from less than 10 oocysts, but 100 oocysts were sufficient for the positive result. The detection efficiency of 10–100 oocysts was not described. These findings confirm the results of other researchers (1), that have shown the disadvantages of sequencing as the final method for the detection in the cases of mixed infections. Mixed infections in cattle are more prevalent than we first assumed.

Santin and Zarlenga (12) described that 44% of the animals, that were *C. parvum* infected, were not identified by conventional SSU rDNA sequencing because of a mixed infection. Therefore they proved that multiplex PCR is a better method to differentiate between zoonotic and non-zoonotic *Cryptosporidium* spp. in cattle and thus it is the key method for public health risk assessment. Moreover, they described the use of *C. parvum* primer set 1010/1011 as advantageous, because the presence of 400 bp amplicon indicates the presence of one of the two species, *C. parvum* and *C. hominis*, which are the most frequently responsible for human cryptosporidiosis.

DNA microarray

DNA microarray is a multiplex technology used in molecular biology and medicine. It consists of an aligned series of great amounts of DNA oligonucleotides (short oligonucleic sequences). These oligonucleids characterize concrete genes and they serve as a template for denatured DNA sample of a patient, in which we want to prove the gene's presence. In case of sufficient affinity between the oligonucleid and fluorescent dye stained DNA sample of a patient, hybridization occurs and the fluorescent dye is recorded

and interpreted by a scanner. Since the microarray can involve ten thousands of probes, the microarray experiment can include many genetic tests in one (5). That is the reason for the major increase of interest in the microarray testing.

DNA microarray is used for: measuring changes at the level of gene expression; the detection of SNPs (single nucleotide polymorphisms); genotyping or resequencing of genome mutants; identifying organisms in samples; and diagnoses of infectious diseases. Concerning *Cryptosporidium* spp., the DNA microarray is used for the identification of *C. parvum* species compared to those, that don't belong to the genus *Cryptosporidium*, as well as for the discrimination among the *C. parvum* genotypes.

Straub *et al.* (15) was monitoring the application of the oligonucleotide microarray method for: the specific detection of *Cryptosporidium* spp.; differentiation among closely related *C. parvum* isolates and cryptosporidial species; and differentiation among human genotypes. They created a microarray with 68 probes that aimed the 7 SNPs in the 190 bp region of HSP70 gene of *C. parvum*. Biotine or Cy3-marked HSP 70 targets were prepared in the PCR reaction. Various genotypes of *C. parvum* as well as DNA of other organisms were used for testing the specificity of the method. The result was that only the DNA from *C. parvum* isolates produced marked amplicons which could be hybridized and detected in the microarray assay. Although the hybridization characteristics among the genotypes were visually different, it was necessary to use statistic analysis of the data showing the intensity of signal in order to identify the SNPs. The result of this study was that the microarray method had a potential to differentiate among various genotypes of isolates and species on one microarray.

This method is very useful in the screening of large amounts of environmental samples for various environmental pathogens. Lee *et al.* (7) was examining the waste waters of sewage tanks in Ontario, Canada, and he used the DNA microarray method. They created 21 oligonucleotide sonds for the detection of pathogens that occur most commonly in water. Based on SSU rRNA gene sequence they identified three tested strains of protozoa. The detection limit was 1×10^3 of target genes or 50 *C. parvum* oocysts per reaction. To prove the efficiency of the DNA microarray test, quantitative real-time PCR with functional genes (COWP gene) has been used. The authors managed to create a method for the detection of incompatible group specific environmental pathogens. This method significantly facilitates the monitoring of pathogens found in water resources.

CONCLUSION

The methods presented offered to us the opportunity to investigate cryptosporidial infections and their sources. This study also included aspects of the parasite's systematics, biology, ecology and population genetics, which may lead to improved strategies for the prevention, surveillance and control of human and animal cryptosporidiosis.

ACKNOWLEDGEMENT

This study was supported by project VEGA SR No. 1/0108/10 and 1/0144/10.

REFERENCES

1. Cama, V.A., Arrowood, M.J., Ortega, Y.R., 2006: Molecular characterization of the *Cryptosporidium parvum* IOWA isolate kept in different laboratories. Conference information: 9th International workshop on opportunistic protists. *J. Eukaryotic microbiol.*, 53, 40–42.
2. Coupe, S., Sarfati, C., Hamane, S., Derouin, F., 2004: Detection of *Cryptosporidium* and identification to the species level by nested PCR and restriction fragment length polymorphism. *J. Clin. Microbiol.*, 1017–1023.
3. Fontaine, M., Guillot, E., 2003: Study of 18S rRNA and rDNA stability by real-time RT-PCR in heat-inactivated *Cryptosporidium parvum* oocysts. *FEMS Microbiol. Lett.*, 226, 237–243.
4. Gilson, M.D., Buggy, I., Brian, P.M.D., 1996: Cryptosporidiosis in patients with HIV disease: Is it safe to drink the water? *HIV Newslines* (San Francisco General).
5. Gonzales, S.F., Krug, M.J., Nielsen, M.E., Santos, Y., Call, D.R., 2004: Simultaneous detection of marine fish pathogens by using multiplex PCR and DNA microarray. *J. Clin. Microbiol.*, 42, 1414–1419.
6. Guy, R.A., Payment, P., Krull, U.J., Horgen, P.A., 2003: Real-time PCR for quantification of *Giardia* and *Cryptosporidium* in environmental water samples and sewage. *Appl. Environ. Microbiol.*, 69, 5178–5185.
7. Lee, G.C., Nam, S.H., Chae, J.C., 2009: *Giardia duodenalis*: Improved detection of viable cysts by reverse transcription-PCR of heat shock-inducible hsp70 gene. *Exp. Parasitol.*, 123, 377–380.
8. Nichols, R.A.B., Cambell, B.M., Smith, H.V., 2003: Identification of *Cryptosporidium* spp. oocysts in United Kingdom noncarbonated natural mineral waters and drinking waters by using a modified nested PCR-restriction fragment length polymorphism assay. *Appl. Environ. Microbiol.*, 69, 4183–4189.
9. Pangasa, A., Jex, A.R., Campbell, B.E., Bott, N.J., Whipp, M., Hogg, G. *et al.*, 2008: High resolution melting-curve (HRM) analysis for the diagnosis of cryptosporidiosis in humans. *Mol. Cell. Probes*, 23, 10–15.
10. Poulson, M.D., Wittwer, C.T., 2007: Closed-tube genotyping of apolipoprotein E by isolated probe PCR with multiple unlabelled probes and high-resolution DNA melting analysis. *Biotechniques*, 43, 87–91.
11. Robinson, G., Thomas, A.L., Daniel, R.G., Hadfield, S.J., Elwin, K., Chalmers, R.M., 2006: Sample prevalence a molecular characterisation of *Cryptosporidium andersoni* within a dairy herd in the United Kingdom. *Vet. Parasitol.*, 142, 163–167.
12. Santin, M., Zarlenga, D.S., 2009: A multiplex polymerase chain reaction assay to simultaneously distinguish *Cryptosporidium* species of veterinary and public health concern in cattle. *Vet. Parasitol.*, 166, 32–37.
13. Stanley, K.K., Szewczuk, E., 2005: Multiplexed tandem PCR: gene profiling from small amounts of RNA using SYBR green detection. *Nucleic Acids Res.*, 33, 180.
14. Stiles, J.I., Lemme, C., Sondur, S., Morshidi, M.B., Manshardt, R., 1993: Using randomly amplified polymorphic DNA for evaluating genetic relationships among papaya cultivars. *Theor. Appl. Genet.*, 85, 697–701.
15. Straub, T.M., Daly, D.S., Wunshel, S., 2002: Genotyping *Cryptosporidium parvum* with an hsp70 single-nucleotide polymorphism microarray. *Appl. Environ. Microbiol.*, 68, 1817–1826.
16. Sulaiman, I.M., Morgan, U.M., Thompson, R.C.A., Lal, A.A., Xiao, L., 2000: Phylogenetic relationships of *Cryptosporidium* parasites based on the 70-kilodalton heat shock protein (HSP70) gene. *Appl. Environ. Microbiol.*, 66, 2385–2391.
17. Walker, N.J., 2002: Tech.Sight. A technique whose time has come. *Science*, 296, 557–559.
18. Welsh, J., McClellan, M., 1990: Fingerprinting genomes using PCR with arbitrary primers. *Nucleic Acids Res.*, 18, 7213–7218.
19. Williams, A., Kubelik, K., Livak, J., Rafalski, S., Tingey, 1990: DNA polymorphisms amplified by arbitrary primers are useful as genetic markers. *Nucleic Acids Research*, 18, 6531–6535.
20. Xiao, L., Escalante, H., Yang, C.F., Sulaiman, I., Escalante, A., Montali, R.J., Fayer, R., Lal, A.A., 1999: Phylogenetic analysis of *Cryptosporidium* parasites based on the small-subunit rRNA gene locus. *Appl. Environ. Microbiol.*, 65, 1578–1583.

Received January 31, 2011

ULTRASTRUCTURAL CHANGES IN THE *M. GASTROCNEMIUS* OF JAPANESE QUAILS DURING LONG-LASTING HYPODYNAMY

Holovská, K. jr., Almášiová, V., Tarabová, L., Cigánková, V.

Institute of Histology and Embryology, University of Veterinary Medicine and Pharmacy
Komenského 73, 041 81 Košice
The Slovak Republic

kholovska@uvlf.sk

ABSTRACT

The aim of this study was to observe the influence of simulated microgravity (hypodynamy) on the ultrastructure of the *m. gastrocnemius*. On the second day after hatching, the chicks were exposed to hypodynamy. Experimental and control chicks were killed on days 56 and 126. The focal morphological change on day 56 in the experimental group was the alterations of the internal structure of mitochondria. The damaged regions were also characterized by myofibrillar lysis, with disrupted and frayed sarcomeres. On day 126 the *m. gastrocnemius* of the experimental group was less altered than on day 56, indicating some restoration of the initially damaged areas. Gigantic mitochondria were a significant ultrastructural change.

Key words: hypodynamy; *m. gastrocnemius*; mitochondria

INTRODUCTION

Hypodynamy is one of the models used to simulate weightlessness under laboratory conditions on Earth. In birds, it is considered the most suitable and frequent method used for such studies. The process of this method is orienting the Japanese quails in space in such a way so that their legs do not touch the floor but they can freely move their heads, wings and legs. This method allows one to subsequently observe morphological changes in tissues and organs of the experimental animals. The changes result from alterations occurring at the cellular level in these birds, in response to the stress to which they are exposed. The stress induces biochemical changes in cells which can result in a decrease in various systemic processes and subsequently in decreased function and even damage to the

cells. All these changes may be manifested by alterations in the ultrastructure of individual organelles.

This study investigated the influence of hypodynamy on the ultrastructure of the *m. gastrocnemius* in Japanese quails.

MATERIAL AND METHODS

Animals

We used hypodynamy as a method of simulating weightlessness under laboratory conditions on Earth. The experiments were carried out at the Institute of Animal Biochemistry and Genetics of the Slovak Academy of Sciences in Ivanka pri Dunaji. Fifty-six newly hatched Japanese quail males were used. On the second day after hatching, twenty-eight chicks of the experimental group were exposed to hypodynamy as described by Škrobánek *et al.* (14). At the same time, twenty-eight chicks (control group) were placed in a rearing box. Birds from both the experimental and control groups were kept under their respective conditions until days 56 and 126 in a windowless room with controlled ventilation and electrical heating by infrared lamps. The temperature was adjusted to 35–36 °C for the first few days after hatching and gradually lowered to 20 °C at 4 weeks and remained at this level until the end of the experiment. Commercial starter rations HYD-13 and water were available *ad libitum*. The diet was granular and contained 260 g kg⁻¹ protein and 11.5 MJ metabolizable energy kg⁻¹. The lighting in the rearing room was continuous. The care and use of animals were in accordance with the laws and regulations of the Slovak Republic and approved by the Ethical Committee of the Institute of Animal Biochemistry and Genetics, Slovak Academy of Sciences, Ivanka pri Dunaji and the State Veterinary and Food Agency (ŠVPS SR Č. K. Ro-7879/04-220/3).




Fig. 1. Electron micrograph on day 56 — experimental group.
Magn. $\times 7\,500$.
m — mitochondrion, arrow — dilated sarcoplasmic reticulum

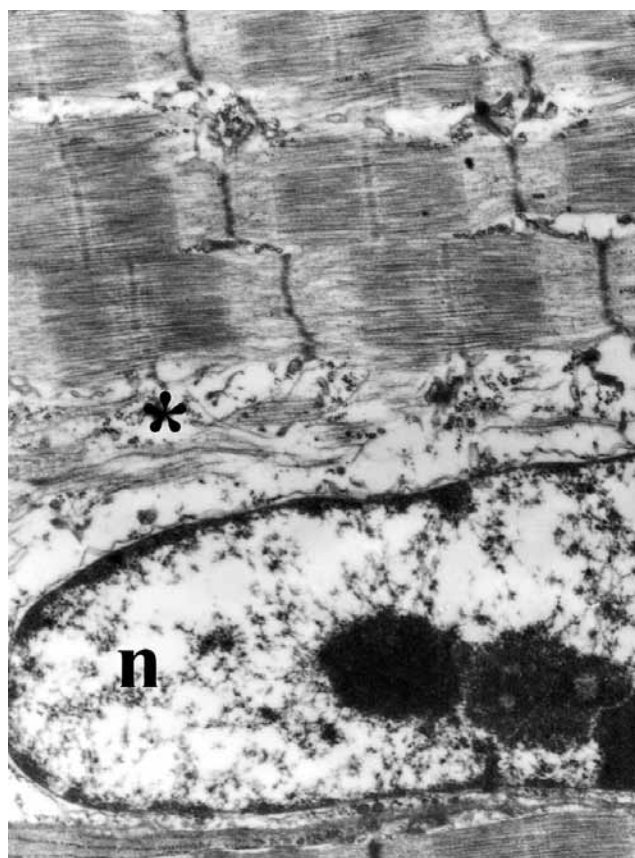


Fig. 2. Electron micrograph on day 56 — experimental group.
Magn. $\times 10\,000$.
asterisk — myofibrils, n — nucleus

Four randomly selected birds from each group were euthanized by cervical dislocation on days 56 and 126. Tissue samples of the *m. gastrocnemius* were collected by small biopsies. Thereafter, the samples were processed for transmission electron microscopy (TEM).

TEM

Samples of the *m. gastrocnemius* were fixed by immersion in 3% glutaraldehyde in cacodylate buffer (pH 7.2), and post-fixed in 1% OsO_4 , dehydrated in acetone and embedded in Durcupan. Ultrathin sections were contrasted with uranyl acetate and lead citrate. Electron micrographs were taken using a TESLA BS 500 electron microscope.

RESULTS

The ultrastructural picture of the *m. gastrocnemius* in the control group on day 56 was as follows. The myofibrils in the longitudinal sections showed pronounced striations caused by alteration of the darker anisotropic (A-zone) and the lighter isotropic (I-zone) zones. Each anisotropic zone contained a centrally located H-band with a dark medially placed M-line. The regular sarcomeres were bounded by Z-lines. The space between the myofibrils contained mitochondria, glyco-

gen and terminal cisternae. Such morphological picture was observed in all control birds and thus, constitutes the normal ultrastructural appearance of skeletal muscle.

On day 56, the experimental birds showed no gross changes in the *m. gastrocnemius* in comparison with the control. However, some ultrastructural changes were seen which were focal and affected only some myofibers. Myofibrils in these myofibers were changed and their course was uneven. Z-lines were frequently discontinuous and in some places completely disintegrated. In these places, we observed myofilament lysis. The extended spaces that were adjacent to them contained disintegrated remains of sarcomeres. Mitochondria of various sizes were accumulated in the spaces between the myofibrils. The structure of many of them was altered; they were enlarged, dilated and their cristae were disturbed. We observed dilatation of the sarcoplasmic reticulum and its disintegration in the most affected locations (Fig. 1, 2).

On day 126 the experimental quails had only small focal changes in the ultrastructure of the muscular tissue. The changes within the foci involved mostly mitochondria and cisternae of sarcoplasmic reticulum. Mitochondria were dilated, coalesced and frequently exceeded the length of 2 sarcomeres. The internal structure of these gigantic mitochondria was changed. The cristae were disintegrated in some places and the internal matrix formed electron-dense aggregates.




Fig. 3. Electron micrograph on day 126, without changes – experimental group. Magn. $\times 10\,000$. m – mitochondrion, arrow – sarcoplasmic reticulum




Fig. 4. Electron micrograph on day 126 – experimental group. Magn. $\times 12\,000$. m – mitochondrion, arrow – sarcoplasmic reticulum

The sarcomeres in these places were irregular with indistinctive isotropic and anisotropic zones (Fig. 3, 4).

DISCUSSION

Many studies have indicated the occurrence of metabolic, functional and structural changes in cells, tissues and organs of animals exposed to weightlessness (hypokinesis, hypodynamy) (1, 6, 13, 17). The morphological picture of the *m. gastrocnemius* observed in this study, also demonstrated some changes depending upon the length of exposure to hypodynamy.

The morphological changes in the *m. gastrocnemius*, observed in the experimental animals on day 56 of age, involved the sarcomeres with the lysis of myofibrils and the accumulation of mitochondria exhibiting distortions of various size and shape. Because the changes described occurred only in some myofibers, we have assumed that the muscular tissue attempted to adapt to the unusual conditions. The mitochondria of skeletal tissue adjust rapidly to various changes and stress. Under stress, their volume increases (4). In parallel with structural changes, mitochondria undergo also functional changes (18). The formation of giant mitochondria is an adaptation process to certain stress situations. Presumably,

free radicals play a decisive role in their production (18). Free radicals, which develop under physiological conditions and increasingly under pathological conditions during various stresses, damage mitochondrial membranes causing coalescence of neighbouring mitochondria and the formation of gigantic mitochondria. By producing these enlarged entities, mitochondria try to decrease the concentration of oxygen and thus also intracellular concentration of oxygen radicals (18). Oxidative stress may damage the sarcoplasmic reticulum, leading to an increase in the intracellular calcium (2, 5, 8, 10) and thus to cause hydrolysis of phospholipids and proteins (11). Free radicals also damage lysosomes, causing the release of lysosomal enzymes and increased muscle atrophy (9). Taillandier *et al.* (16) observed the increased activity of these enzymes in skeletal muscles of hind limb-suspended rats. Free radicals can directly damage proteins (12). Damage to muscle fibres causes the release of metals such as iron from myoglobin which catalysis oxidative processes and accelerates atrophy (7).

Many studies indicate the remarkable ability of muscular tissue to adjust to conditions to which they are exposed (3). This was witnessed by our observation in 126 day old quails which retained the relatively normal structure of myofibers. However, we observed some foci with enlarged mitochondria which coalesced and formed giant mitochondria. A similar

bodily response was observed by Škrobánek *et al.* (15), who investigated the content of the total proteins and glycogen in the skeletal muscles of quails.

CONCLUSIONS

Observation of Japanese quails exposed to lengthy hypodynamy showed morphological changes only in some myofibers. On day 56, the experimental birds exhibited changes mainly in the mitochondria, but also in some sarcomeres due to the disintegration of the myofilaments. These changes gradually disappeared as observed in 126 day old quails. Our results indicated that chicks of Japanese quails adapted to hypodynamy conditions and were capable of developing in simulated weightlessness.

ACKNOWLEDGEMENTS

This work was supported by the Grant Agency for Science of the Slovak Republic, VEGA 1/0334/09.

REFERENCES

1. Cigánková, V., Lenhardt, E., Zibrín, M., Kočíšová, J., Tomajková, E., Komorová *et al.*, 2001: Morphological changes in the small intestine of Japanese quail chicks hatched under the conditions of microgravity. *Folia Veterinaria*, 45, 27–31.
2. Castilho, R., Carvalho-Alves, P., Vercesi, A., Ferreira, S., 1997: Oxidative damage to sarcoplasmic reticulum calcium pump induced by Fe^{2+} (H_2O_2) ascorbate is not mediated by lipid peroxidation or thiol oxidation and leads to protein fragmentation. *Mol. Cell. Biochem.*, 159, 105–114.
3. Glass, D.J., 2011: PI3 kinase regulation of skeletal muscle hypertrophy and atrophy. *Curr. Top Microbiol. Immunol.*, 346, 267–278.
4. Hoppeler, H., Fluck, M., 2003: Plasticity of skeletal muscle mitochondria: structure and function. *Med. Sci. Sports Exerc.*, 35, 95–104.
5. Chowdhury, P., Soulsby, M.E., Scott, J. L., 2009: Effects of aminoguanidine on tissue oxidative stress induced by hindlimb unloading in rats. *Annals of Clinical and Laboratory Science*, 39, 64–70.
6. Kočíšová, J., Cigánková, V., Zibrín, M., Tomajková, E., Lenhardt, E., Sabo, V. *et al.*, 2001: The morphological picture of *m.gastrocnemius* in Japanese quail chicks hatched on the orbital station “Mir”. *Folia Veterinaria*, 45, 32–35.
7. Kondo, H., Nakagaki, I., Sasaki, S., Hori, S., Itokawa, Y., 1993: Mechanism of oxidative stress in skeletal muscle atrophied by immobilization. *Am. J. Physiol.*, 265, 839–844.
8. Liantonio, A., Pierno, S., Digennaro, C., Giannuzzi, V., Gramegna, G., Desaphy, J.F., Camerino, D.C., 2009: The hindlimb unloading model of microgravity differently affects skeletal muscle properties of young and adult mice. *Basic Applied Myology*, 19, 107–112.
9. Mak, I.T., Mirsa, H.P., Weglicki, W.B., 1983: Temporal relationship of free radical-induced lipid peroxidation and loss of latent enzyme activity in highly enriched lysosomes. *J. Biol. Chem.*, 258, 13733–13737.
10. Mourelle, M., Meza, M.A., 1991: CCl_4 -induced lipoperoxidation triggers a lethal defect in the liver plasma membranes. *J. Appl. Toxicol.*, 10, 23–27.
11. Pascoe, G.A., Reed, D.J., 1989: Cell calcium, vitamin E, and the triol redox system in cytotoxicity. *Free Radic. Biol. Med.*, 6, 209–224.
12. Reid, M., 1996: Reactive oxygen species and nitric oxide in skeletal muscle. *News in Physiological Science.*, 11, 114–119.
13. Saxena, R., Pan, G., Dohm, E.D., McDonald, J.M., 2011: Modeled microgravity and hindlimb unloading sensitize osteoclast precursors to RANKL-mediated osteoclastogenesis. *Journal of Bone and Mineral Metabolism*, 29, 111–122.
14. Škrobánek, P., Hrbatá, M., Baranovská, M., Juráni, M., 2004: Growth of Japanese quail chicks in simulated weightlessness. *Acta Veterinaria Brno*, 73, 157–164.
15. Škrobánek, P., Baranovská, M., Šárniková, M., Juráni, M., 2007: Effect of simulated microgravity on metabolite concentrations in the muscles and liver of developing Japanese quail chicks. *Acta Veterinaria Brno.*, 76, 9–16.
16. Taillandier, D., Auroousseau, E., Meynial-Denis, D., Bechet D., Ferrara M., Cottin P. *et al.*, 1996: Coordinate activation of lysosomal, Ca^{2+} -activated and ATP-ubiquitin-dependent proteinases in the unweighted rat soleus muscle. *Biochem. J.*, 316, 65–72.
17. Zibrín, M., Cigánková, V., Kočíšová, J., Tomajková, E., Komorová, T., Lenhardt *et al.*, 2001: The structure of some tissues and organs of Japanese quail chicks hatched on the orbital space station “Mir”. *Folia Veterinaria*, 45, 17–22.
18. Wakabayashi, T., 2002: Megamitochondria formation – physiology and pathology. *Journal of Cellular and Molecular Medicine*, 6, 497–538.

Received June 16, 2011



DIROFILARIA IMMITIS INFECTION IN A THREE YEAR OLD DOBERMAN: A CASE REPORT

**Ajadi, R. A.¹, Omobowale, T. O.², Igado, O. O.²
Adejinmi, J. O.², Adedokun, O. A.², Nottidge, H. O.¹**

¹College of Veterinary Medicine, University of Agriculture, Abeokua

²Faculty of Veterinary Medicine, University of Ibadan, Ibadan
Nigeria

bukitayo_omobowale@yahoo.com

ABSTRACT

A three-year-old male Doberman that was presented at the Veterinary Teaching Hospital of the University of Ibadan, Nigeria with the complaint of anorexia, bloody diarrhea and weight loss was diagnosed with a chronic form of heartworm disease based on the findings at the physical examination which included a complete blood count, liver function tests and thoracic radiography. The physical examination revealed that the dog's mucous membranes were pale and there was a copious bilateral mucopurulent ocular discharge present. There was subcutaneous oedema on the ventral thoracic region, while auscultation revealed tachypnea and an irregular heart rhythm. The results of the hematology and liver enzyme tests revealed moderate anaemia, which was normochromic and normocytic. There was mild neutrophilia, eosinopaenia and monocytopenia. Both the alkaline phosphatase (ALP) and aspartate transaminase (AST) were markedly elevated. Also, the serum albumin concentrations and the albumin/globulin ratio were both markedly lowered. The direct blood smear revealed that the dog was negative for both *Babesia canis* and *Ehrlichia canis*, but positive for microfilaria. The microfilaria was $309 \pm 30 \mu$ in length and the anterior and posterior widths were $12 \pm 2.4 \mu$ and $9 \pm 1.6 \mu$, respectively. The lateral thoracic radiograph showed that the heart was normal in size, while the pulmonary vasculatures were visible and within normal range. The health of the dog improved following treatment with levamisole and gentaprim. This case confirms the efficacy of levamisole in combination with gentaprim in the management of canine heart worm disease.

Key words: levamisole; *Dirofilaria immitis*; Doberman

INTRODUCTION

Dirofilariosis, also known as heartworm infection, is caused by a slender filaroid nematode, *Dirofilaria immitis* (2). Although the disease has been reported in domestic cats, wolves, foxes, captive sea lions, coyotes, non-domestic cats and man, dogs are considered to be the only definitive host (2, 16). Humans as well as several other mammals act as accidental hosts in which the life cycle is not complete (4). Transmission of the parasite is mainly by bites from mosquitos of the genera *Aedes*, *Anopheles* and *Culex* (5, 6). The female worms are ovoviviparous and shed microfilariae into the blood stream, where they circulate for up to two to five years or until they are taken up by blood sucking culicidae with a blood meal. It takes approximately two weeks and two moults within the mosquito for the microfilaria (L1) to develop into the infective L3 stage. When a potential host is bitten by a mosquito, the infective L3 larva enters the host and within 70–110 days, the L3 stages would have completed their somatic migration into the host thorax and undergone two moults into the L5 stage. The L5 larvae enters the vascular system via penetration of peripheral veins to reach the pulmonary arteries and take another three months before it develops into an adult worm (14).

The pathology of heartworm infection is influenced by: the number of adult worms; duration of infection; shear stress of high blood flow associated with exercise; location of the worms; and the host immune status (8, 14). Three forms of the disease have been reported. Typically, heartworm disease occurs in dogs of any age, but it is commonly seen in dogs older than five years and which have had a long-standing or concurrent infection (2). The caval

syndrome is an acute disorder of young immature dogs in which large numbers of adult worms accumulate in the right atrium, vena cava and hepatic vein rather than the pulmonary artery (6). This is characterized by intravascular hemolysis, disseminated intravascular coagulation (DIC) and shock (14). The asymptomatic form of the disease has been associated with the early form of the disease in which there is insufficient number of adult worms in the pulmonary trunk (16). This form accounts for the vast majority of the total heartworm infection (1). Occasionally, ectopic infections in which adult worms were found in the anterior chamber of the eye, the skin and the central nervous system (CNS) have been reported (14).

Interest in the study of heartworm infection has grown recently because of the increasing incidence of the infection and the public health implications (11, 16). *D. immitis* infection is spreading progressively from the regions of sub-tropical climate to temperate areas (1). Within the last 20 years, *D. immitis* was reported to be endemic in America, Africa, Asia, Australia and Southern Europe (12). Imported cases of *D. immitis* infections have been reported from the United Kingdom, Netherlands, Sweden, Hungary, Austria and Germany. Although heartworm infection is reported to be worldwide in distribution, it is not commonly reported in Nigeria. This paper reports a case of dirofilariasis in a three-year-old Doberman characterized by ventral subcutaneous oedema, diarrhoea and elevated liver enzymes, and treated with a single dose of levamisole hydrochloride at 4 mg.kg⁻¹ body weight and Gentaprim.

CASE REPORT

Anamnesis

A three-year-old male Doberman was presented at the Veterinary Teaching Hospital of the University of Ibadan, Nigeria, with the complaint of anorexia, bloody diarrhea and weight loss. The dog was the only animal in the house and used mainly for security. The dog also came from an area not previously reported to be endemic for heartworms but endemic for mosquitoes. The owner did not observe any sign of coughing prior to this complaint. The dog had in the past been routinely wormed with mebendazole, ivermectin or levamisole hydrochloride. The dog had also been vaccinated against rabies, canine distemper, canine hepatitis and leptospirosis.

Clinical findings

The physical examination revealed that the dog's mucous membranes were pale and a copious bilateral mucopurulent ocular discharge was present. The coat was rough with a moderate tick infestation and subcutaneous oedema was noticed in the ventral thoracic region. In addition, the dog was emaciated with a consistent rectal temperature ranging from 38.3°C to 38.6°C. There was tachypnea (86 breaths per min) with an irregular heartbeat (72 beats per min). However, there was no ascites or jugular pulse.

Diagnosis

Ten millilitres of blood were taken from the cephalic vein and divided into ethylene diamine tetra-acetic acid (EDTA) and plain tubes for complete blood count, haemoparasite de-

tection and liver enzyme tests. In addition, both faeces and urine were collected for helminthes egg detection using the floatation technique and urinalysis using the dip sticks method (Mission Xpert, ACON Laboratories, USA). When microfilaria was detected on direct blood smears, another 5 mls of blood was obtained to confirm this diagnosis and classify the type of microfilaria using a Knott's test (4). Also, both left and right lateral and dorsoventral thoracic radiographs were also obtained using a portable X-ray machine (Philip, Practex).

The result of the hematology and liver enzyme tests (Table 1) showed that the dog had moderate anaemia, which was normochromic and normocytic. There was mild neutrophilia, eosinopaenia and monocytopenia. Both the alkaline phosphatase (ALP) and aspartate transaminase were markedly elevated. Also the serum albumin concentrations and the albumin/globulin ratio were both markedly lowered. The direct blood smear showed that the dog was negative for both *Babesia canis* and *Ehrlichia canis*, but positive for micro-

Table 1. Result of complete blood count and liver function test of the infected dog compared with reference values

Parameters	Infected dog	Reference values
PCV [%]	15	37–55
RBC [$\times 10^{12}.l^{-1}$]	3.5	5.5–8.5
MCV [fl]	68	60–77
MCHC [g.dl ⁻¹]	33.2	32–36
WBC [$10^9.l^{-1}$]	14.4	6–17
Neutrophils [$10^9.l^{-1}$]	12.2	3–11.4
Monocytes [$10^9.l^{-1}$]	0	0.15–1.35
Eosinophils [$10^9.l^{-1}$]	0	0.1–0.75
Lymphocytes [$10^9.l^{-1}$]	2.2	1–4.8
ALP [IU. l ⁻¹]	698	0–98
ALT [IU. l ⁻¹]	70	0–57
AST [IU. l ⁻¹]	192	0–48
Total proteins [IU. l ⁻¹]	5.9	5.5–7.5
Albumin [IU.l ⁻¹]	1.9	2.6–4.0
A. G. ratio	0.47	About 1

PCV – packed cell volume; RBC – red blood cells counts; MCV – mean corpuscular volume; MCHC – mean corpuscular haemoglobin concentration; WBC- white blood cell counts; ALP – alkaline phosphatase; ALT – alanine transaminase; AST – aspartate transaminase; A. G. ratio – albumin-globulin ratio

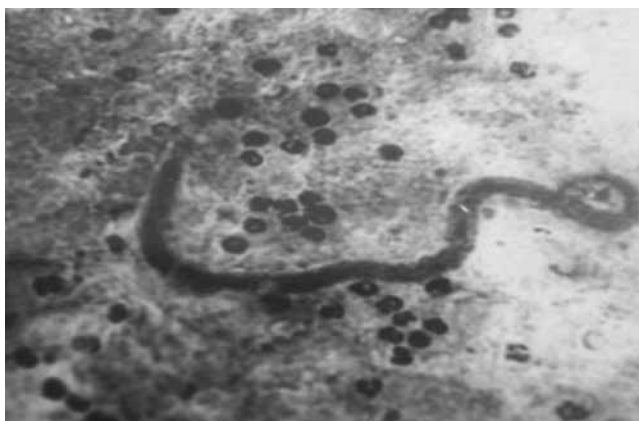


Fig. 1. Photomicrograph of a blood smear showing microfilaria of *Dirofilaria immitis*

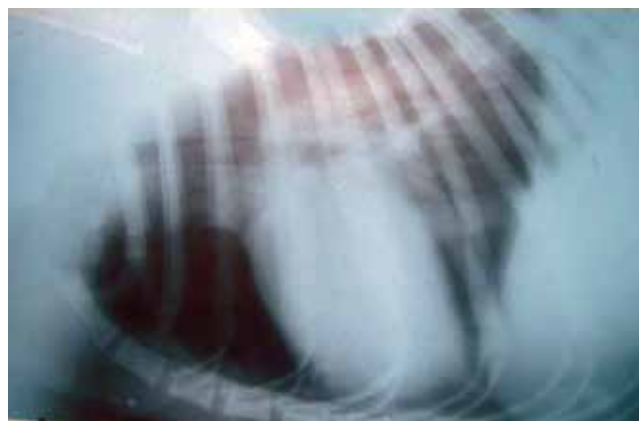


Fig. 2. Lateral radiograph of the chest. Note heart and vessel size are within normal limit

filaria with severe parasitemia (Fig. 1). The microfilaria was $309 \pm 30 \mu$ in length and the anterior and posterior widths were $12 \pm 2.4 \mu$ and $9 \pm 1.6 \mu$, respectively. Also the result of the fecal examination was negative for helminthes egg, while the urinalysis result was normal for all the parameters determined. The lateral thoracic radiographs (Fig. 2) showed that the heart was normal in size (vertebral heart score VHS=9.4). The pulmonary vasculature were visible and within normal range. Lung lobes were well aerated with the normal interstitial pattern.

Therapy

The dog was treated with a single subcutaneous injection of levamisole hydrochloride (Levadex®, Pantex) at the rate of 4 mg.kg^{-1} and combination therapy of Gentamycin, Trimethoprim and Sulphadimethoxazine (Gentaprim®, Invesa) at the rate of 5 mg.kg^{-1} body weight once daily for five days. Serial blood samples were obtained and screened for microfilaria on days 7, 9 and 11 post treatment.

The health of the dog improved following treatment with levamisole and gentaprim. Microfilaria were absent from the blood samples collected on days 7, 9 and 11 post treatment. The dog was discharged to the owner about two weeks after presentation and there has been no complaint of illness since then.

DISCUSSION

Anorexia, weight loss, lethargy, exercise intolerance, cough and dyspnoea are common signs associated with heartworm disease (2, 6). The dog in this report also presented with diarrhea, anemia and irregular heart rhythm. The heart rhythm may be associated with the moderate anemia or an indication of an early cardiac dysfunction probably secondary to the heart worm infection. An electrocardiographic examination would have indicated the type of arrhythmia; however it was not performed in this case. The exact link between the heartworm disease and the diarrhea in the dog is unknown.

The diarrhoea cannot be attributed to helminth infection since the fecal examination was negative for helminthes egg. However, it is of interest to note that the diarrhea stopped following administration of levamisole and gentaprim. In addition, the ventral subcutaneous oedema may be suggestive of congestive heart failure

About fifteen adult worms would be required to produce the disease with clinical signs in dogs (14). Factors eliminating the number of adult worms present include destruction of worms by host immune reactions and the destruction of microfilaria by macrolides such as ivermectin (15). It is logical to say that the dog in this report presented a stage II chronic heart worm disease characterized by anaemia and congestive heart failure. Although, we were unable to determine the number of adult worms from the pulmonary arteries and right ventricles of the dog, the severity of the disease in this dog may be related to the age and the routine use of macrolides as antihelminthics.

Radiographic examination is often carried out as part of the diagnostic protocol for dogs with heartworm disease to determine the severity of the cardiovascular involvement. The usual findings may include pulmonary arterial enlargement and right ventricular enlargement (3). The result of the radiographic examination did not reveal any change in chamber dimension or pulmonary vasculature suggesting that the thoracic radiograph of the dog was normal and that cardiovascular involvement in the disease was very minimal. However, it should be noted that pulmonary radiographs could be normal in up to 14% of symptomatic dirofilariasis cases (14). The radiographic findings may be associated with the number of worms in the pulmonary artery (8).

The result of the liver test and serum protein was suggestive of liver disease. Elevated hepatic enzymes and hypoalbuminemia are findings reported in 10–30% of heartworm disease (2, 5). It is however surprising that in spite of the moderate hypoalbuminemia; the urine of the dog was negative for protein. The hypoalbuminemia may however be associated with protein losing gastro-enteropathy with the attending diarrhoea.

The management of heartworm disease is either directed towards the elimination of the infective larva stage (microfilaria) or the adult worms. Melarsormine, an adulticidal organoarsenical compound is the drug of choice for the treatment of canine heart worm disease due to its efficacy and safety (9). The drug was reported to be safe with a mean retention time five times longer than thiacetarsemide (10). Macrolide agents such as ivermectin and mibemycin, as well as, levamisole are effective microfilaricidal drugs commonly used for the treatment and prophylaxis against canine heart worm infection. It is of interest to note that the administration of 4 mg/kg¹ levamisole hydrochloride and daily injections of Gentaprim[®] resulted in the disappearance of microfilaria from the peripheral blood and an improvement in the clinical signs. This further confirms the efficacy of levamisole has a microfilaricidal agent, and may probably be due to its immune modulating effect. This finding also suggested that routine use of levamisole hydrochloride and ivermectin in this environment might have been responsible for the putative low prevalence status of heartworm infection in Nigeria.

Finally, heartworm infection is zoonotic. Human cases of heartworm infection have been reported to be increasing due to increased traveling to heartworm endemic areas (6, 7). Worldwide, approximately 150 cases of heart worm infections have been reported, mostly from Japan and the USA (13). The isolation of *Dirofilaria immitis* in this dog further stresses the need to carry out a serological survey on dogs to ascertain the true prevalence of the disease in Nigeria. In conclusion, the combination of levamisole and gentaprim was found to be effective against the clinical signs produced by chronic heartworm infection in the dog.

REFERENCES

1. Aranda, C., Panyella, O., Eriyja, R., Castella, J., 1998: Canine filariasis. Importance and transmission in the Baix Llobregat area, Barcelona (Spain). *Vet. Parasitol.* 77, 267–275.
2. Atkins, C., 2005: Canine heartworm disease. In Ettinger, S. J., Feldman, E. C. (eds.): *Textbook of Veterinary Internal Medicine*, 6th edn., 1118–1136 pp.
3. Bahr, R. J., 2007: Heart and pulmonary vessels. In Thrall D. E. (ed.): *Textbook of Veterinary Diagnostic Radiology*. Saunders, Elsevier, Missouri, USA, 568–590.
4. Calvert, C. A., Rawlings, C. A., McCall, J. W., 1999: Canine Heartworm Disease. In Fox, P. R., Sisson, D., Moise, S. N. (eds.): *Textbook of Canine and Feline Cardiology*. Philadelphia, W. B. Saunders Co., 702–726.
5. Dillon, R., Brawner, W. R., Hanrahan, L., 1996: Influence of number of parasites and exercise on the severity of heartworm disease in dogs. In Proc. *Heartworm Symposium '95*. Batavia, Ill, American Heartworm Society. 113 pp.
6. Dillon, R., 2000: *Dirofilaria immitis* in dogs and cats. In Ettinger, S. J., Feldman, E. C. (eds.): *Textbook of Veterinary Internal Medicine*, 5th edn., 937–963.
7. Foroulis, C. N., Khaldi, L., Desimonas, N., Kalafati, G., 2005: Pulmonary dirofilariasis mimicking lung tumor with chest wall and mediastinal invasion. *Thorac. Cardiovasc. Surg.*, 53, 173–175.
8. Genchi, C., Rinaldi, L., Gascone, M. C., Mortarino, M., Gringoli, G., 2005: Is heartworm disease really spreading in Europe? *Vet. Parasitol.*, 13, 137–148.
9. Hettlich, B. F., Ryan, K., Bergman, R. L., 2003: Neurologic complications after melarsormine dihydrochloride treatment for *Dirofilaria immitis* in three dogs. *J. Am. Vet. Med. Assoc.*, 223, 1456–1461.
10. McCall, J. W., McTier, T. L., Ryan, W. G., Gross, S. J., Soll, M. D., 1996: Evaluation of Ivermectin and Milbemycin oxime efficacy against *Dirofilaria immitis* infections of three and four month duration in age. *Am. J. Vet. Res.*, 57, 1189–1192.
11. McCall, J. W., Genchi, C., Kramer, L. H., Guerrero, J., Venco, L., 2008: Heartworm disease in animals and humans. *Adv. Parasitol.*, 66, 193–285.
12. Montoya, J. A., Moralis, M., Juste, M. C., Banares, A., Simon, F., Genchi, C., 2006: Seroprevalence of canine heartworm disease (*Dirofilaria immitis*) on Tenerife Island: an epidemiological update. *Parasitol. Res.*, 100, 103–105.
13. Saron, F. M., Atxuguin, C. M., Morchon, R., Martin, J. R., 2004: What is happening in other parts of the World regarding human dirofilariasis? *Symposium of the American Heartworm Society*, Philadelphia, 137 pp.
14. Schrey, C. F., Trautvetter, E., 1998: Canine and feline heartworm disease- diagnosis and therapy. *Waltham Focus*, 8, 23–30.
15. Schwan, E. V., Durand, D. T., 2002: Canine filariasis caused by *Dirofilaria immitis* in Mozambique: a small survey based on the identification of microfilaria. *J. S. Afr. Vet. Assoc.*, 73, 124–126.
16. Theiss, I. H., 2005: Public health aspects of *Dirofilaria immitis* in the United States. *Vet. Parasitol.*, 133, 157–180.

Received September 27, 2010

INFLUENCE OF CADMIUM AND SELENIUM ON THE ACTIVITY OF TRYPSIN AND CHYMOTRYPSIN IN THE DROPPINGS OF JAPANESE QUAILS

Korének, M., Koréneková, B., Skalická, M., Naď, P., Sokol, J., Jalč, P., Húska, M.

University of Veterinary Medicine and Pharmacy, Komenského 73, 041 81 Košice
The Slovak Republic

korenekova@uvm.sk

ABSTRACT

The aim of this study was to observe the effect of cadmium (Cd) and selenium (Se) on the activity of chymotrypsin (ACHT) and trypsin (AT) in the droppings of Japanese quails. The birds (24) were divided into 4 groups of 6 each. The animals in group 1 (G1) received 0.12 mg Cd.day⁻¹ per quail in the drinking water, whereas those in group 2 (G2) were given 4 mg Se.day⁻¹. The quails in group 3 (G3) were supplied a combination of 0.12 mg Cd.day⁻¹ and 4 mg Se.day⁻¹. The quails in group 4 (G4) were not given any supplements, acting as controls. The ACHT and AT were determined after day 1, 35 and 58 of supplementation. The addition of Cd in the drinking water resulted in the inhibition of ACHT and AT ($P < 0.001$) in group G1 compared to the control. The selenium showed a positive effect on the increase in ACHT ($P < 0.001$) and AT ($P < 0.001$) in groups 2 and 3. The significantly higher ($P < 0.001$) ACHT and AT were observed in group G3 supplemented with Cd and Se, compared to group G1 supplemented with Cd. Our results indicated that the long-term supplementation of Se can positively affect the level of ACHT and AT after Cd treatment in the droppings of Japanese quails.

Key words: cadmium; chymotrypsin; Japanese quail; selenium; trypsin

INTRODUCTION

Cadmium is an important industrial and environmental contaminant in the biosphere that can produce a wide variety of adverse effects in humans and animals. Cadmium causes tissue damage, as well as functional and structural changes in the kidneys, liver, lungs,

bones, ovaries and foetal development (14, 17). Cadmium induces toxicity and teratogenicity in animals (25). This toxic element causes an oxidative deterioration of biological macromolecules and decrease antioxidant enzyme levels (20). Cadmium is bound to the sulfhydryl (-SH) groups of proteins. It can affect various metabolic processes, especially energy metabolism, membrane transport and protein synthesis (7).

The toxic effects of cadmium may be mediated by selenium (Se). Se is an essential trace element, which is a component of selenoproteins e.g. glutathione peroxidase, thioredoxin reductase or iodine (16). Se is well known as a modifying factor in the toxicity of metal compounds (27). Animal experiments have indicated an interaction between Se and Cd. These experiments show that Se prevents the acute damaging effects of Cd. Se completely protected the male reproductive system against Cd induced damages (28). The separate administration of Cd causes the increase in Se content in the tissues of rats and also Se administration results in a decrease in Cd kidney content (26).

Pancreatic protease, chymotrypsin and trypsin are proteolytic enzymes acting in the digestive systems. These endopeptidases are synthesized in the pancreas by protein biosynthesis. Trypsin and chymotrypsin enter the intestine in the form of the inactive proenzymes trypsinogen and chymotrypsinogen, respectively. If these enzymes are inhibited, nutrient malabsorption occurs (15). Cd inhibits the activity of many enzymes, such as catalase, mitochondrial ATP-ase, alkaline phosphatase, some proteases, dehydrogenases and chymotrypsin in poultry droppings (13). The determination of chymotrypsin and trypsin activity in the faeces is relevant to pancreatitis, lung diseases and some other pathological changes (3).

Quail belong to the family *Phasianidae* of the order *Galliformes*. The domesticated subspecies, *Coturnix coturnix japonica*, is

called Japanese quail. Quails are to be found in all of the continents. A number of lines, breeds and varieties have been developed for different productive purposes. Japanese quails are raised for their tasty meat and nutritional eggs all over the world. The prevailing breeds in Europe and the USA are those of the combined productive purposes and of the predominately meat production type (6). Due to their unique experimental advantages, such as short hatching cycle, rapid growth and reproduction, and distinctive adaptability to microgravity, quails are suitable as animal model experimental subjects (1, 8, 2). Quails have been used for the investigation of physiological processes in the body of fowls and have appeared suitable for observations of the interactions between essential chemical elements and xenobiotics under *in vivo* conditions (10). The aim of this study was to observe the activity of chymotrypsin and trypsin in droppings of Japanese quails after long-term administration of cadmium and selenium.

MATERIAL AND METHODS

Twenty-four 40-day-old Japanese quails, weighing about 170 g each, were included in the experiments. All experiments were performed observing the ethical requirements for animal handling approved by the University of Veterinary Medicine and Pharmacy in Košice, the Slovak Republic. The experimental conditions complied with ethical standards, animal welfare and the proper care of animals. Japanese quails were used as model animals because they are similar to wild birds and are a better indicator of environmental exposure than rodents, which are kept strictly under laboratory conditions.

The quails were kept in cages under optimum microclimate conditions optimal for their growth. They were fed a complete mixed feed for poultry HYD-10 (manufactured in Agrofarm Product s. r. o., Slanská Huta, the Slovak Republic) as a full-value feed, throughout the experiment. The feed mixture was provided *ad libitum*. Composition of the feed is given in Table 1. It complied with the Regulation of the Government of the Slovak Republic, No. 440/2006 (21). The mean feed consumption was about 40g feed.day⁻¹ per quail and the mean weight of the birds was 170 g.

The Cd content in the feed (0.007 mg.kg⁻¹) and water (0.001 mg.l⁻¹) used in this study were below the maximum permissible limits for Cd in feeds in the Slovak Republic (0.5 mg.kg⁻¹ at 12 % moisture) and the drinking water (0.003 mg.l⁻¹) complied with the Regulations of the Government of the Slovak Republic No. 347 and 438/2006 (21). Thus the birds were not exposed to Cd through their diet or drinking water.

Experimental design

Soluble salts of SeCl₄.3H₂O and CdCl₂.H₂O (extra pure, Merck, Germany) were used without further purification to prepared stock solutions in 1 litre of distilled water from which the selected doses contained in 1 ml, were given to birds in their drinking water.

The quails were divided into 4 groups of 6 each. The first experimental group (G1) was administered a solution of CdCl₂.H₂O at a dose of 0.12mg Cd.day⁻¹. The second group (G2) was given a solution of SeCl₄.3H₂O at a dose of 4 mg Se.day⁻¹ and the third group (G3) received both elements (Cd + Se); Cd at a dose of 0.12 mg Cd.day⁻¹ and Se at dose of 4 mg Se.day⁻¹. The fourth group (G4) was supplied tap water without any supplements and served as controls.

Table 1. Composition of commercial feed supplied to Japanese quails

Composition	Value (g.kg ⁻¹)	Minerals	Value (mg.kg ⁻¹)	Vitamins	Value (mg.kg ⁻¹)
Crude protein	153	Zinc	60	A	8,000 IU.kg ⁻¹
Energy	11.5 MJ.kg ⁻¹	Calcium	45	D ₃	1 600 IU.kg ⁻¹
Ash	160	Phosphorus	5.0	E	10 mg.kg ⁻¹
Fiber	60	Sodium	2.5	B ₂	4.0 mg.kg ⁻¹
Lysine	7.0	Manganese	40	B ₁₂	10 µg.kg ⁻¹
Methionine +cystine	6.0	Iron	40		
Methionine	3.5	Copper	4.0		
Linoleic acid	15				

The analysis of specific activity of chymotrypsin and trypsin

The specific activity (U.g⁻¹) of chymotrypsin (AChT) and trypsin (AT) in the droppings of Japanese quails was determined by the methods described by Rosival *et al.* (22). The measurements were carried out after day 1, 35 and 58 of supplementation with the investigated elements (Cd, Se) at the time of maximum production of eggs (11–14 weeks of age).

The chymotrypsin activity was determined after hydrolysis of the chromogenic substrate Succinyl-(Gly)₂-Phe-p-nitroanilide and the activity of trypsin after hydrolysis of L-TAPA (Tosyl-Arg-p-nitroanilide). Chymotrypsin (trypsin) was extracted from 1g fresh mixed droppings, using 10 ml of 0.5 mol.l⁻¹ NaCl with 0.1 mol.l⁻¹ CaCl₂.

The suspension obtained was centrifuged for 5 min at 5 000 g and the supernatant was used as an enzyme source. An extract aliquot (0.1 ml) was added to 0.1 ml of substrate dissolved in buffer (1.8 ml) by which the reaction was initiated. The rapidity of chymotrypsin (trypsin) catalysed hydrolysis of Succ-(Gly)₂-Phe-pNA or trypsin catalysed hydrolysis of L-TAPA (Tosyl-Arg-pNa) was established kinetically at 405 nm on a Specol 200 (Karl Zeiss Jena, Germany). The sensitivity of the method used for the determination of chymotrypsin and trypsin was 0.5–1.0 µg.ml⁻¹ at the starting concentration of the substrate, and 1 mmol.l⁻¹ in the reaction media under optimal reaction conditions (pH 7.8–8.0, temperature 25 °C). The results obtained were analysed statistically by the Student *t*-test (Microsoft Excel 7.0), setting the significance levels at P<0.05, P<0.01 and P<0.001. The data are presented as means ± standard deviation.

RESULTS

Activity of trypsin

The long-term administration of Cd to Japanese quails in group G1 (Table 2) resulted in significant ($P < 0.001$) inhibition of the activity of trypsin ($102.8; 113.1 \text{ U.g}^{-1}$) compared to the control group G4 ($116.4; 125.2 \text{ U.g}^{-1}$).

On the other hand, a significant increase ($P < 0.001$) activity of trypsin was observed in droppings of quails in group G2 with addition of Se after 35 days (279.9 U.g^{-1}) as well as after 58 days (282.4 U.g^{-1}) compared to the control group G4.

Similarly, a significantly increased ($P < 0.001$) activity of trypsin was observed in group G3 with addition of Cd + Se after 35 as well as after 58 days of the experiment ($198.1; 152.3 \text{ U.g}^{-1}$) compared to the control group G4. The protective effect of selenium caused an increase in the trypsin activity compared to group G1 which received the Cd only.

Table 2. Effect of Cd, Se, and Cd-Se supplementation on the activity (U.g^{-1}) of trypsin in quail's droppings

Experimental group	Activity of trypsin	Day 1	Day 35	Day 58
G1	Cd	98.3 ± 7.4	$102.8 \pm 6.5^{***}$	$113.1 \pm 5.2^{***}$
G2	Se	$122.3 \pm 7.0^{***}$	$279.9 \pm 6.9^{***}$	$282.4 \pm 8.4^{***}$
G3	Cd + Se	$120.5 \pm 7.8^{***}$	$198.1 \pm 6.9^{***}$	$152.3 \pm 5.1^{***}$
G4	Control	101.3 ± 7.6	116.4 ± 6.6	125.2 ± 5.2

Statistical significance: *** $P < 0.001$

Table 3. Effect of Cd, Se, and Cd-Se supplementation on the activity (U.g^{-1}) of chymotrypsin in quail's droppings

Experimental group	Activity of chymotrypsin	Day 1	Day 35	Day 58
G1	Cd	100.5 ± 6.1	$135.3 \pm 7.8^{***}$	$132.1 \pm 7.7^{***}$
G2	Se	$159.3 \pm 8.4^{***}$	$189.0 \pm 8.8^{***}$	$200.8 \pm 6.3^{***}$
G3	Cd + Se	$152.8 \pm 6.1^{***}$	$185.0 \pm 5.5^{***}$	$187.8 \pm 4.9^{***}$
G4	Control	102.5 ± 6.3	160.4 ± 7.6	177.1 ± 7.7

Statistical significance: *** $P < 0.001$

Activity of chymotrypsin

The cadmium application in group G1 markedly reduced the activity of chymotrypsin during the experiment (Table 3). A significantly lower activity of chymotrypsin ($P < 0.001$) was detected in group G1 after 35 as well as after 58 days of the experiment ($135.3; 132.1 \text{ U.g}^{-1}$) compared to the control group G4 ($160.4; 177.1 \text{ U.g}^{-1}$).

The activity of chymotrypsin in group G2, with addition of Se was significantly higher ($P < 0.001$) after 35 as well as after 58 days of the experiment ($189.0; 200.8 \text{ U.g}^{-1}$) compared to the control group G4.

A significant increase ($P < 0.001$) was observed after addition of Cd + Se in group G3 after 35 as well as after 58 days of the experiment ($185.0; 187.8 \text{ U.g}^{-1}$) compared to the activity in the G4 group.

The results of our study revealed an increase in the activity of trypsin and chymotrypsin (G1–G4) at the end of experiment in comparison with the beginning of experiment. The activities of chymotrypsin and trypsin depended on the increasing age of quails.

DISCUSSION

The inhibitory effect of Cd on the activity of chymotrypsin and trypsin was observed in our experiments. Cd markedly decreased the activity of pancreatic proteases. A similar inhibitory effect of Cd on the activity of chymotrypsin was confirmed in the droppings of laying hens after 6 months exposure to Cd (9) and on trypsin after Cd supplementation to broilers as demonstrated by Kosa *et al.* (11, 12). The effect of Cd exposure on the activity of pancreatic protease activities in rats were studied by Shimada *et al.* (24). They observed that Cd inhibited protease activities within the pancreas *in vivo* at doses that do not induce overt hepatic, renal or pancreatic toxicity. Based on *in vitro* studies, the decreases seen in trypsin and chymotrypsin activities might be based on the indirect effects of Cd, whereas the decrease in carboxypeptidase A, was probably due to the direct inhibition by the metal.

In our study, the addition of Se caused competitive activation of chymotrypsin and trypsin in the droppings. This positive effect of Se treatment on the activity of proteases was observed after 1st day of application and during all experiments with Japanese quails. The addition of Se acted also as an agonist against the toxic effects of Cd. Se was found to have a protective effect against Cd by increasing the activity of chymotrypsin and trypsin in the middle as well as at the end of the study.

The metabolism and function of essential elements can be markedly altered by the competition for binding position ligand sites in biological systems. The deficiency of essential elements results in dysfunction, but their excess may also be harmful. However, at higher doses, Cd blocks the metabolism of these elements and competes with them for some intercellular bonds (23). Se and Cd form a non-toxic high molecular weight complex in the blood. In the next step, Cd is distributed to various organs, especially to the liver, kidneys

and testes, in which it exists as a Cd-metallothionein form. It was found that Se promotes Cd excretion (19).

Selenium can also be an effective antioxidant (4). This has also been proposed as a possible factor in cadmium tolerance. The mechanism of the protective effects of Se on Cd toxicity and increased Se content in organs like liver and kidneys after Cd intake can be explained by the antagonism to Cd-induced DNA damage and by the fact that Se is an essential constituent of a number of enzymes, some of which have antioxidant functions. A deficiency of the element in animals makes them susceptible to injury by certain types of oxidative stresses (5). Se has a strong tendency to form complexes with heavy metals and it has been suggested that the protective effects of selenium are due to the formation of such complexes with Cd. This protection includes the capability of Se to alter the distribution of Cd in tissues and induces binding of the Cd-Se complexes to proteins, which are similar to metallothioneins (18).

CONCLUSION

The results of this study indicate that Cd significantly inhibits the activities of pancreatic proteases, such as trypsin and chymotrypsin. These proteases play an important role in animal digestion. On the other hand, Se supplementation increased the activity of chymotrypsin and trypsin in the droppings of quails. The results of this study revealed the protective effect of Se against the inhibitory effect of Cd on the activity of pancreatic proteases.

ACKNOWLEDGEMENT

The study was supported by the project VEGA 1/0403/08.

REFERENCES

1. Almášiová, V., Tarabová, L., Holovská, K., Cigánková, V., Račeková, E., 2011: Morphological changes in the spongy bone of Japanese quails after 90 days of hypodynamy. *Folia Veterinaria*, 55, 1, 16–19.
2. Baumgartner, J., Hetényi, L., 2001: *Japanese quail*, (In Slovak). VÚŽV, Publ. house Slovenský chov, Nitra, 75 pp.
3. Baret, A. J., Rawlings, N. D., Woessner, J. F., 2003: *The Handbook of Proteolytic Enzymes*. 2nd edn., Academic Press, 220 pp.
4. Bjelakovic, G., Nikolova, D., Gluud, L. L., Simonetti, R. G., Gluud, C., 2008: Antioxidant supplements for prevention of mortality in healthy participants and patients with various diseases. *Cochrane Database of Systematic Review*, 2, CD 007176.
5. Burk, R. F., 2002: Selenium, an antioxidant nutrient. *Nutrition Clinical Care*, 2, 2002, 75–79.
6. Genchev, A. G., Ribarski, S. S., Afanasjev, G. D., Blohin, G. I., 2005: Fattening capacities and meat quality of Japanese quails of Pharaoh and White English breeds. *Journal of Central European Agriculture*, 6, 4, 495–500.
7. Hijová, E., Ništiar, F., 2005: Plasma antioxidant changes after acute cadmium intoxication in rats. *Acta Veterinaria Brno*, 74, 565–569.
8. Holovská, K., Almášiová, V., Cigánková, V., 2010: Environmental stress and effect on the structure of liver animals. In *Proceedings The 10th International Scientific Conference Risk Factors of Food Chain*, 13–14th September, Nitra, Slovakia, 123–125.
9. Korének, M., Vaško, L., Koréneková, B., Jacková, A., Skalická, M., Siklenka, P., et al., 2000: Effect of vitamin D₃ on chymotrypsin activity in the dropping of laying hens after an exposure to cadmium. *Bulletin of the Veterinary Medicine in Pulawy*, 44, 227–235.
10. Koréneková, B., Skalická, M., Naď, P., Korének, M., 2004: Breeding and history of Japanese quails (In Slovak). *Magazín chovatela* (Breeder's Magazine), 8, 46–47.
11. Kosa, E., Rigo, I., Csutoras, L., Szakacs, A., 2004: Laboratory investigations on effects of different concentrations of cadmium in broiler chickens. *Trace Elem. Electrolytes*, 4, 211–214.
12. Kosa, E., Fekete, S., Papp, Z., 2000: Effect of cadmium intake on some digestive enzyme activities in broiler chickens. *Methods Enzymol.*, 234, 214–217.
13. Krejpcio, Z., Trojanowska, E., 2000: The effect of lead and cadmium ion on pepsin and trypsin activity *in vitro*. *Bromatology Chemical Toxicology*, 33, 44–47.
14. Kukner, A., Colakoglu, N., Kara, H., Oner, H., Ozogul, C., Ozan, E., 2007: Ultrastructural changes in the kidney of rats with acute exposure to cadmium and effects of exogenous metallothionein. *Biol. I Trace Elem. Res.*, 119, 137–146.
15. Layer, P., Keller, J., 1999: Pancreatic enzymes: Secretion and luminal nutrient digestion in health and disease. *J. Clin. Gastroenterol.*, 28, 3–10.
16. Ledvina, M., Stoklasová, A., Cerman, J., 2009: *Biochemistry for medical students I* (In Czech). UK Prague, Karolinum, 546 pp.
17. Massányi, P., Lukáč, N., Uhrín, V., Toman, R., Pivko, J., Rafay, et al., 2007: Female reproductive toxicology of cadmium. *Acta Biol. Hung.*, 58, 287–299.
18. Ognjanović, B., Marković, S. D., Pavlović, S. Z., Zikic, R. V., Stajin, A. S., Sacić, Z., 2008: Effect of chronic cadmium exposure on antioxidant defence system in some tissues of rats: protective effect of selenium. *Physiol. Res.*, 57, 403–411.
19. Ohta, H., 1985: The protection mechanisms of selenium treatment against the acute cadmium toxicity secondary role of metallothionein. *Acta Scholae Medcinialis Universitatis in Gifu*, 33, 5, 931.
20. Paniagua-Castro, N., Escalona-Cardoso, G., Hernandez-Navarro, D., Pérez-Pasten, R., Chamorro-Cevallos, G., 2011: Spirulina (*Arthrospira*) protects against cadmium induced teratogenic damage in mice. *Journal of Medicinal Food*, 14, 398–404.
21. Regulations of the Government of the Slovak Republic, 347, 438 and 440/ 2006.
22. Rosival, I., Šulík, E., Šlesárová, L., Korének, M., Blahovec, J., 1993: Determination of chymotrypsin activity in animals stools. *Folia Veterinaria*, 37, 19–22.
23. Stec, J., 2000: Inhibition of DNA repair by cadmium and lead in sheep lymphocytes: protective interaction of magnesium. *Bulletin of the Veterinary Institute in Pulawy*, 44, 221–226.

24. Shimada, H., Funakoshi, T., Waalkes, M., 2000: Acute nontoxic cadmium exposure inhibits pancreatic protease activities in the mouse. *Oxford Journals Life Science & Medicine Toxicological Sciences*, 53, 474–480.

25. Šutiaková, I., Šulík, E., Rimková, S., Sakalíková, A., Šutiak, V., 2001: Micronucleus frequency in cytokinesis-blocked bovine lymphocytes from regions with different pollution levels in Slovakia. *Bull. Environ. Contam. Toxicol.*, 66, 449–455.

26. Toman, R., Golian, J., Šiška, B., Massányi, P., Lukáč, N., Adamkovičová, 2009: Cadmium and selenium in animal tissues and their interactions after experimental administration to rats. *Slovak Journal of Animal Science*, 42, 115–118.

27. Yoo, Y. Ch., Lee, S. K., Yang, J. A., Kim, K. W., Lee, S. Y., 2002: Interrelationship between the concentration of toxic and essential elements in Korean tissues. *Journal of Health Science*, 48, 195–200.

28. Włodarczyk, B., Minta, M., Biernacki, B., Szkoda, J., Zmudzki, J., 2000: Selenium protection against cadmium toxicity in hamster embryos. *Polish Journal of Environmental Studies*, 9, 323–327.

Received July 14, 2011